

A Study on Clinical Profile of Intestinal Obstruction in a Tertiary Care Hospital

Srinivas Rao¹, Santhosh Kumar Shanti^{2*}

¹Associate Professor, Department of Surgery, LNCT Medical College, Indore, Madhya Pradesh, India.

²Associate Professor, Department of Surgery, Santiniketan Medical College, Bolpur, West Bengal, India.

ABSTRACT

Background: Intestinal obstruction is one of the common surgical emergencies. Acute intestinal obstruction occurs either mechanically from blockage or from intestinal dysmotility when there is no blockage sometimes it is called as functional. Acute intestinal obstruction accounts for 1-3% of all hospital admissions. In more than 80% of cases of obstruction, small bowel is involved. Strangulation of bowel leads to vascular insufficiency. Extrinsic causes of obstruction in the United States and European countries are surgical adhesions, carcinomas, or herniation of anterior abdominal wall. Colonic volvulus is more common in Africa and Russia than United States.

Aim of the Study: To study the Etiology and clinical features of Acute intestinal obstruction in a teaching hospital.

Materials & Methods: We have conducted this study in LNCT Medical College Hospital, Indore in the department of General Surgery, for 1 year. We have examined total 70 no. of patients, out of these 70, Male patients were 48 and Female patients were 22. The age group involved is between 20 years and 70 years.

Results: We have examined 70 patients out of this 70, 48 patients were Males and 22 were Female patients. The age

group in between 20 years and 70 years, 6 patients were expired.

Conclusion: Acute intestinal obstruction is very common emergency condition in Surgical practice. Surgical adhesions are common cause for obstruction. Strangulation leads to vascular insufficiency which may be fatal.

Key Words: Large Intestine, Transverse Colon, Distention, Constipation, Small Intestine.


*Correspondence to:

Dr. Santhosh Kumar Shanti,
Associate Professor,
Department of Surgery,
Santiniketan Medical College,
Bolpur, West Bengal, India.

Article History:

Received: 04-11-2021, Revised: 27-11-2021, Accepted: 23-12-2021

Access this article online

Website: www.ijmrp.com	Quick Response code 
DOI: 10.21276/ijmrp.2022.8.1.010	

INTRODUCTION

Acute Intestinal Obstruction is one of the common Surgical emergency conditions worldwide. More than 80% of cases involves small bowel. Mechanical obstruction is due to blockage and functional obstruction is due to intestinal dysmotility.¹ About of 1/3 of cases may have Ischemia, due to Strangulation. 8-10% Mortality rate is seen in strangulated cases when surgery is conducted within 24 hours. The intussusception is most common cause of obstruction in pediatric age group. In old age group the mortality is high. The common extrinsic causes for obstruction are Post operative adhesions, Malignancies, Intraperitoneal abscess and idiopathic sclerosis, Intrinsic causes may be due to inflammatory bowel disease and schistosomiasis. Small bowel obstruction slightly common in Females² more than 50% of obstructions are caused by post operative adhesions, neoplasms cause 21.5%, hernias causes 12% volvulus, intussusception causes 13% and inflammatory bowel diseases causes around 5%. Post operative adhesions usually caused by open type of

surgeries than laparoscopic type. Around 25% cases are Managed conservatively and approx. 35% are Managed surgically.

Common clinical features include abdominal pain, distention of abdomen. Vomiting, constipation diarrhea, Fever, tachycardia, hypotension, severe pain and signs of peritoneal irritation are in favor of strangulations.³ Patients with Ileus or Pseudo obstruction may have signs and symptoms similar to bowel obstruction, distention in present but colicky type of pain abdomen is absent. Increased mortality is seen with strangulation, Sepsis. Metabolic acidosis most common cause for death in the intestinal obstruction. CT Scan of abdomen is having the major role in the diagnosis.

MATERIALS & METHODS

We have conducted this study in LNCT Medical college hospital, in the department of General surgery for 1 year. We have included

total no. of 70 patients out of those 70 patients, 48 are males and 22 patients were females. The common age group involved is between 20 years and 70 years. After taking complete history, we have examined all the patients and advised investigations like complete blood picture, random blood sugar, blood urea and serum creatinine, plain x-ray abdomen erect posture, ultrasound abdomen and CT Scan abdomen, all the data is collected, computerized systemically by using MS Office informed consent has been obtained by attendants by giving the consent forms in their local language.

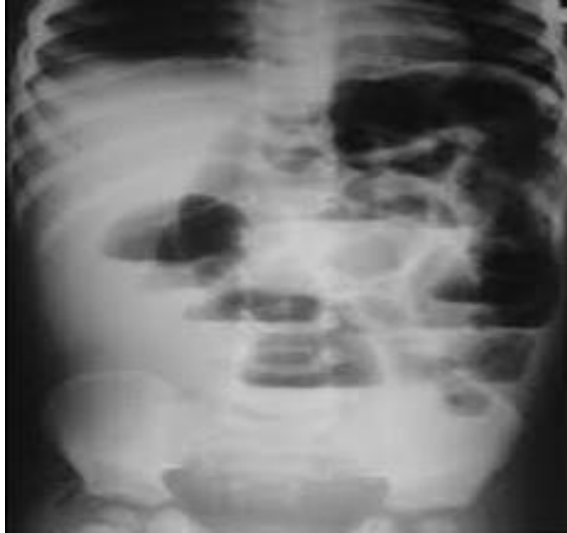

Fig 1: Air Fluid Levels in Intestinal Obstruction

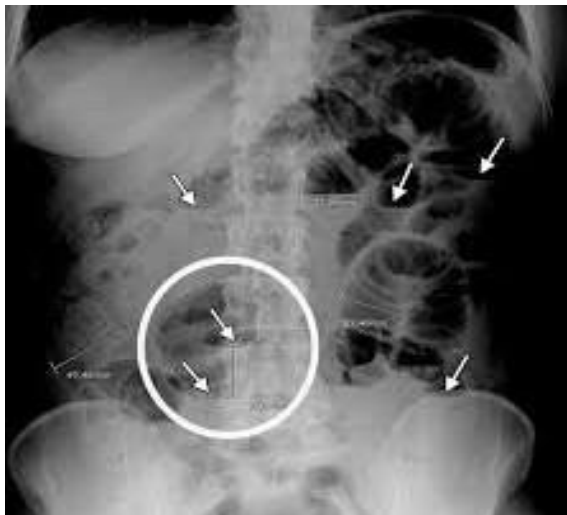


Fig 2: Multiple Air Fluid Levels in Intestinal Obstruction

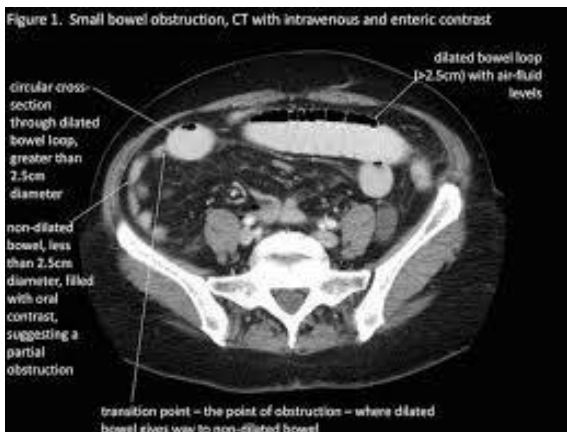

Fig 3: CT Scan in Small Bowel Obstruction

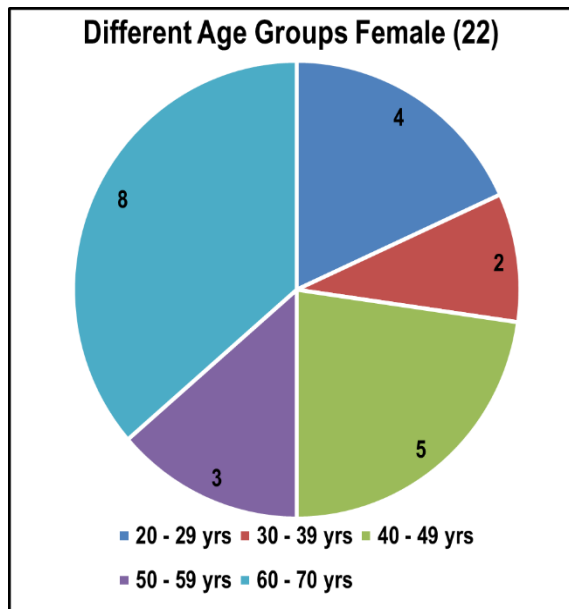
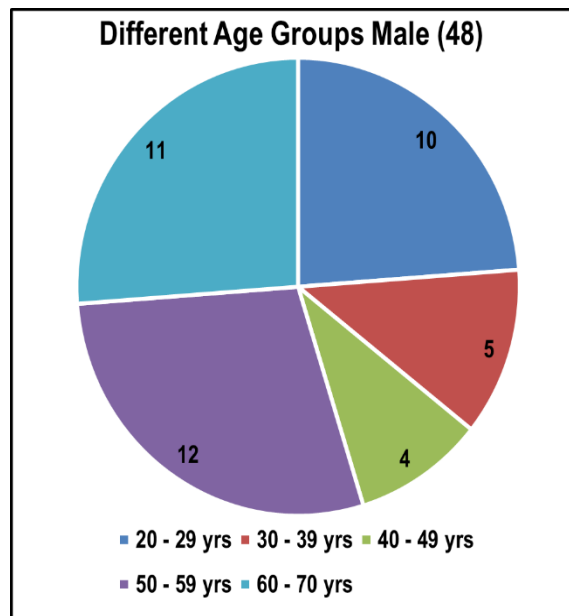
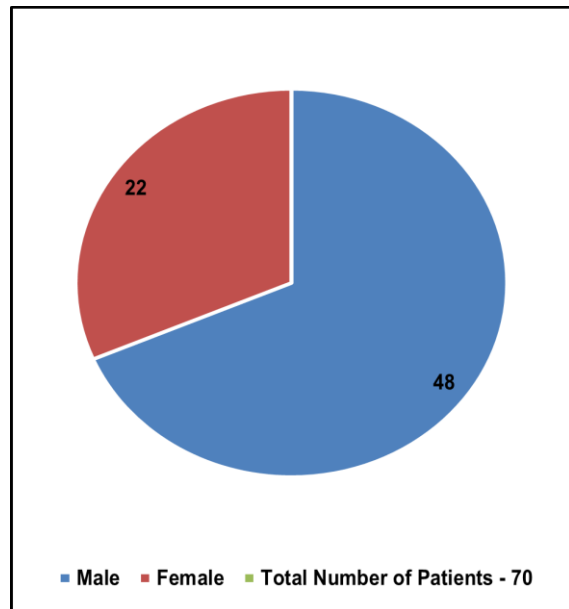


Table I: Different age groups

Age group in years	Male (48)	Female (22)
20-29	10 (20.5%)	4 (8.15%)
30-39	5 (10.25%)	2 (9.50%)
40-429	4 (8.12%)	5 (22.75%)
50-59	12 (25.8%)	3 (13.5%)
60-69	11 (22.25%)	8 (35.8%)

Table II: Clinical Features

Clinical features	Male (48)	Female (22)
Distention of abdomen	48 (100%)	22 (100%)
Pain abdomen	40 (83.2%)	17 (75.9%)
Vomitings	37 (77.3%)	14 (64.9%)
Others	31 (64.5%)	15 (68.2%)

Table III: Different Sites of Lesions

Site of Lesion	Male (48)	Female (22)
Large Bowel	12 (26.07%)	6 (27.5%)
Small Bowel	36 (83.3%)	16 (82.5%)

Table IV: Causes of Obstruction

Causes	Male (48)	Female (22)
Adhesions	28 (58.4%)	10 (45.4%)
Carcinoma	10 (20.8%)	6 (27.8%)
Benign Masses	6 (12.5%)	4 (18.5%)
Others	4 (8.2%)	2 (9.5%)

RESULTS AND DISCUSSION

We have examined total 70% patients (48) Males (22) Female Patients. The age group is between 20 years and 70 years. The maximum age group involved is between 50 years and 70 years. (47.9%) in Males and (43.5%) in Females. The study conducted by Hayanga AJ et al shows 53.6 % and 47.3% respectively.⁴ The clinical features we observed in our study are distention of abdomen 100%; pain abdomen 83.2% in Males and 75.9% in Females; vomitings observed 77.3% in Males and 64.7% in Females; other factors like fever, tachycardia., hypotension is also observed. The observations made by Rana Sv et al shows almost similar results like distension is seen in 97.5%.⁵ The study conducted by Isvinn TT et al shows pain abdomen 92.7%; vomitings 81.5%; pain abdomen in 82.3%.⁶ In our study large bowel involved in more than 20% patients and small bowel is nearly 80% patients. The causes of obstruction we noticed are post operative adhesions in Males 28 no. (58.4%) in females 10 no. (45.4%); carcinoma in male patients 10 no. (20.8%). In females 6 no. (27.5%); being masses in males 6 in no. (12.5%) and in 4 female patients (18.5%). The studies made by Wangenstein OH et al shows, obstructions due to adhesions are nearly 56.5% and carcinomas are 17.2%; masses and other causes are nearly 20%.⁷ The mortality is 9.2% because of Ischemia and perforation of bowel.

Intestinal obstruction is common surgical emergency condition. It accounts for nearly 22% of total cases. Surgical adhesions are

most common cause (>50%) for obstruction. Partial obstruction may be due to decreased intestinal motility. The mechanism of intestinal obstruction depends on nature of underlying cause, its location and interference in the blood flow. The important characteristic features are increased intestinal contractility which occurs proximal and distal to the obstruction.⁸ Swallowed air is the primary contributor to intestinal distention, but intraluminal air also accumulates from fermentation, local Co₂ production, and altered gaseous diffusion. Intra luminal dilation also increases intraluminal pressure, when luminal pressure exceeds venous pressure, venous and lymphatics drainage is impaired. Ultimately arterial blood supply may becomes compromised which leads to Ischemia, necrosis and perforation. Stasis increases the bacterial counts in the Jejunum and Ileum. The most common organisms are E. Coli; streptococcus feacalis and klebsiella.⁹ The important clinical features includes distention of abdomen, colicky type of pain abdomen, vomitings, and constipation. The proximal obstruction may have vomitings early, whereas distal part of obstruction will have pain and distention because of greater reservoir of intestine. Bloating and abdominal discomfort will be seen in early obstruction. Tachycardia and hypotension may be due to sepsis. Bowel sounds will be increased in early cases. In erect abdomen x-ray multiple loops of small bowel with a paucity of gas in large bowel and air fluid level in step ladder pattern is seen. But x-ray abdomen accurately diagnose the intestinal

obstruction upto 60% cases only. Whereas CT scan of abdomen plays major role in the diagnosis. CT Scan can define the cause and level of obstruction in most patients. Thickened intestinal walls poor flow of contrast media into a sector of bowel suggest ischemia, and pneumoperitoneum suggest perforation.¹⁰ During management we have opted conservative and surgical methods. conservative management in stable patients and with history of abdominal surgery. We have started intravenous isotonic fluids with oral restriction, bladder catheterization was done to monitor urine output. Intravenous. Antibiotics Metronidazole, ceftriaxone was given to prevent intestinal overgrowth. We have managed conservatively 42.5%. Male patients and 46.9% in females. During surgical management we have used minimally invasive surgical techniques with laparoscopy. With this technique complications are low; hospital stay has decreased, and the cost of health care also decreased.

CONCLUSION

Intestinal obstruction is a common emergency in surgical practice more than 20% cases are due to obstruction in surgical ICU. Post operative adhesions are most common cause for obstruction. Small bowel involves in more than 80% cases. CT Scan Abdomen plays major role in diagnosis. More than 30% patients can be managed medically. Minimally invasive surgery with laparoscope is very much useful in surgical management.

REFERENCES

1. Harrison's Principle's of Internal Medicine 2015;19th edi. Vol II, Chap. 344; PP 1981-86.
2. Short Practice of Surgery by Bailey and Love. 1997; 22nd ed. Chap 8; PP 569-73.

3. Penswan S. Ghoor AM et al. Acute emergencies clinical overview Ind. J. Sing. 1978; 140;182-9.
4. Hayang AJ, Bass K, et al. Current Management of Small bowel obstruction J. AM Coll Radiol 2006; 3 (11): 838-841.
5. Rana SV, Bhardwaj SB. Small intestinal over growth. Scan J. Gastro enterol 2008; 43(9): 1030-37.
6. Irvin TT. Et al Abdominal pain; A surgical audit of 1190 emergency admissions Br. J. Surg. 1989; 76 (11): 1121 – 25.
7. Wangersteen OH.et al. Understanding the bowel obstructions problem. Am J. Sing (978; 135(2): 131-49.
8. T Suyukiy, Ando. T.et al. Clinical study of strangulation of small bowel obstruction Am surj. 2004; 70(1): 40-4.
9. Jackson PG, Rajji M. Evaluation and Management of intestinal obstruction. AM Farm phy. 2011; 83(2) 159-65.
10. Fidler J Mr. Imaging of small bowel. Radiol clin north AM 2007, 45(2): 317-31.

Source of Support: Nil. **Conflict of Interest:** None Declared.

Copyright: © the author(s) and publisher. IJMRP is an official publication of Ibn Sina Academy of Medieval Medicine & Sciences, registered in 2001 under Indian Trusts Act, 1882.

This is an open access article distributed under the terms of the Creative Commons Attribution Non-commercial License, which permits unrestricted non-commercial use, distribution, and reproduction in any medium, provided the original work is properly cited.

Cite this article as: Srinivas Rao, Santhosh Kumar Shanti. A Study on Clinical Profile of Intestinal Obstruction in a Tertiary Care Hospital. Int J Med Res Prof. 2022 Jan; 8(1): 43-46.
DOI:10.21276/ijmrp.2022.8.1.010