

Immunohistochemical Evaluation of Thyroid Transcription Factor (TTF-1) in Lung Carcinoma in Bangladeshi Patients

Purabi Sarkar^{1*}, Mohammad Zillur Rahman², Mohammad Ismail Hossain³, Rumana Mahmud⁴, Syeda Nabila Islam Juthee⁵, Siddhartha Baowaly⁶

¹Assistant Professor, Department of Pathology, Ad-Din Akij Medical College, Boyra, Boikaly, Khulna, Bangladesh.

²Professor, Department of Pathology, Bangabandhu Sheikh Mujib Medical University (BSMMU), Dhaka, Bangladesh.

³Assistant Professor, Department of Pathology, Chittagong Medical College, Chittagong, Bangladesh.

⁴Lecturer, Department of Pathology, Chattogram Maa-O-Shishu Medical College, Chattogram, Bangladesh.

⁵Assistant Professor, Department of Pathology, Parkview Medical College, Sylhet, Bangladesh.

⁶Assistant Registrar, Department of Nephrology, Khulna Medical College Hospital, Khulna, Bangladesh.

ABSTRACT

Background: TTF-1 (Thyroid Transcription Factor-1) is a tissue-specific transcription factor expressed in normal thyroid and lung. In the lung, TTF-1 is involved in the regulation of surfactant protein production. In the adult lung, TTF-1 is expressed in the nonciliated bronchiolar epithelial cells and type II cells and involved in the transcription of the surfactant protein genes in alveolar cells. The 2015 WHO classification recognizes four major histologic subtypes: squamous Cell Carcinoma (SCC), adenocarcinoma (ADC), large Cell Carcinoma and small Cell Carcinoma. Due to the recent advances in targeted therapies, subclassification of lung cancer has become increasingly important.

Objectives: The purpose of this study was assessment of thyroid transcription factor (TTF-1) in Lung Carcinoma in Bangladeshi patients.

Methodology: This cross-sectional observational study was conducted in the Department of Pathology, Chittagong Medical College, Chattogram from March 2018 to February 2020. In this study, fifty-one biopsy samples of lung carcinoma were collected, processed, stained with hematoxylin, and eosin. Periodic Acid Schiff stain was used to evaluate the mucin in adenocarcinoma & adenosquamous carcinoma. All data were recorded in a pre-designed data sheet. Statistical analyses were carried out by using SPSS version 23 for Windows. A descriptive analysis was performed for all data. Observations were indicated by frequencies and percentages. Statistical significance was set at a "p" value < 0.05.

Results: In this study, the mean (\pm SD) age of the patients was 59.73 (\pm 9.71) years with the minimum and maximum age of the patient were 38 years and 75 years respectively. A male predominance was observed in the series (86.3%). With regards to histological classification, 72.5% of patients had identified squamous cell carcinoma, 23.5% of patients had

identified adenocarcinoma and only 2.0% of patients had identified as adenosquamous carcinoma and another 2.0% had small cell carcinoma. SCCs were more prevalent among males than females. In case of TTF-1 immunostaining, 21.6% of patients were positive and 78.4% of patients were negative. Out of 37 squamous cell carcinoma patients, 94.6% of patients were negative and 5.4% of patients were positive by TTF-1 immunostaining. Moreover, due to the very limited number of adenosquamous carcinoma & small cell carcinoma, it was not possible to comment on the utility of TTF-1 in such carcinoma.

Conclusion: TTF-1 was found as a very sensitive and highly specific marker for the diagnosis of adenocarcinoma. So, TTF-1 should be considered when confronted with a poorly differentiated pulmonary neoplasm of uncertain phenotype on bronchoscopic biopsy. A large-scale prospective study with standardized techniques is desirable to validate the findings of the present study.


Key words: Lung Tumors, Adenocarcinoma, Cell Carcinoma, Bronchoscopic Biopsy.

*Correspondence to:

Dr. Purabi Sarkar,
Assistant Professor,
Department of Pathology,
Ad-Din Akij Medical College,
Boyra, Boikaly, Khulna, Bangladesh.

Article History:

Received: 12-08-2021, Revised: 08-09-2021, Accepted: 30-09-2021

Access this article online	
Website: www.ijmrp.com	Quick Response code 
DOI: 10.21276/ijmrp.2021.7.5.003	

INTRODUCTION

Thyroid Transcription Factor-1 (TTF-1) is a tissue-specific transcription factor expressed in normal thyroid and lung¹. In the

lung, TTF-1 is involved in the regulation of surfactant protein production². In the adult lung, TTF-1 is expressed in the

nonciliated bronchiolar epithelial cells and in type II cells and involved in the transcription of the surfactant protein genes in alveolar cells³.

Thyroid transcription factor-1 (TTF-1) is the thyroid specific nuclear transcription factor of the thyroglobulin and thyroperoxidase genes⁴. It has been shown to be commonly expressed also in carcinomas of thyroid and lung origin. The immunohistochemical nuclear expression of TTF-1 is considered to be a useful tool because of its high specificity (95–100%).

TTF-1 is widely used as a pulmonary adenocarcinoma marker in surgical specimens. TTF-1 immunostaining has a sensitivity ranging from 58% to 76% in the detection of pulmonary adenocarcinoma in tissue biopsy specimens⁵. Whereas TTF-1 staining in primary pulmonary SCC has been reported to be variable, ranging from 0% to 38%⁶. Recent studies showed the prognostic value of TTF-1 expression. In the subgroups of patients having adenocarcinoma, TTF-1 expression is associated with better survival⁷. Traditionally, histochemical stain PAS is used to visualize mucin for diagnosis of adenocarcinoma in morphologically unclear cases⁸. The ability to combine other histochemical stains with immunohistochemical staining may prove to have additional advantages. The accurate pathologic classification of lung cancer is important for the evaluation of treatment modalities⁹. Adenocarcinoma and SCC are the two major subtypes of non-small cell lung carcinoma¹⁰. So, it is important to distinguish between adenocarcinoma and SCC because effectiveness of target specific treatments¹¹. Monoclonal antibody inhibitor of vascular endothelial growth factor and epidermal growth factor receptors-tyrosine kinase inhibitors are different for adenocarcinoma and SCC. For example, Bevacizumab, a VEGF drug, an important drug in the treatment of Adenocarcinoma. But for SCC, this drug may cause life threatening haemorrhages¹¹. For diagnostic and therapeutic approach, Immunohistochemistry is a highly effective tool for diagnosis of lung carcinoma. This study aimed at evaluating the effectiveness of TTF-1 for accurate distinction of lung carcinoma. In Chittagong city, this immunostaining will help to remove the diagnostic dilemma of the physician. So, far known there was no such previous study in Bangladesh.

OBJECTIVES

General Objectives

Immunohistochemical assessment of thyroid transcription factor (TTF-1) in Lung Carcinoma in Bangladeshi patients.

Specific Objectives

- 1) To see the histopathological features of carcinoma of lung.
- 2) To study the different histological subtypes of lung carcinoma.
- 3) To evaluate the expression of TTF-1 in lung carcinoma.

METHODOLOGY

Type of Study: Hospital based cross sectional descriptive study

Place of Study: Department of Pathology, Chittagong Medical College and Care Investigation, Chittagong

Study Period: March, 2018 to August, 2020

Study Population: All patients with histopathologically diagnosed as lung carcinomas in the Department of Pathology of Chittagong Medical College, Chittagong during specified time duration comprised of the study population.

Sampling Technique: Consecutive sampling.

Inclusion criteria

1. Patients with histopathologically diagnosed as lung carcinomas.
2. Patients who had given written informed consent.

Exclusion Criteria

1. Patients who had not given consent.
2. Those who had received chemotherapy or radiation therapy for lung carcinoma.
3. Inadequate tissue in block.

Data Collection

It was a cross sectional descriptive study in which the bronchoscopic biopsy material had taken after getting the permission from Institutional Review Board. Then, after taking properly informed written consent from the patient attending in the Department of Pathology, Chittagong Medical College during June 2018 to July 2019, this study was started. Patients with surgically resected lung carcinoma were selected for this study.

The biopsy tissue was fixed in 10% formalin. Tissue processing was done in the Department of Pathology of Chittagong Medical College following standard protocol. All sections were examined under light microscope and reporting was done. After obtaining the histopathological result eligible patients were invited to participate in the study. After taking informed consent a brief history was taken from each patient with particular reference to the age, occupation, smoking history, family history and presenting complains. History regarding alcohol, industrial exposure and past history also recorded.

Data Analysis

After compilation, the data was presented in the form of tables by meticulous checking and rechecking. Statistical analysis of the results was done by using computer based statistical software, SPSS 23.0.0 version (SPSS Inc, Chicago, IL, USA). Results were shown as table and expressed as frequency & percentage for qualitative data and mean \pm SD for quantitative data and McNemar test was applied for compared of the two markers (p63 expression & TTF-1 immunostaining) with histopathological examination. Validity tests (Sensitivity, Specificity, Positive Predictive Value, Negative Predictive Value & Accuracy) with 95% confidence interval were calculated for the two markers on the basis of pathological diagnosis. A 'p' value <0.05 was considered as statistically significant because of all analysis were consider as 95% confidence level.

RESULTS

An analysis of 51 cases of lung carcinoma was done in the Department of Pathology, Chittagong Medical College to evaluate the diagnostic role of TTF-1 immunostaining.

Table 1 showed the distribution of the patients according to socio-demographic variables (n=51). Among 51 patients, most of the patients in this study were in the age group between 51 to 60 years (n=22, 43.1%) followed by age group between 61-70years (n=15, 29.4%). The mean (\pm SD) age of the patients was 59.73 (\pm 9.71) years with range of 38 and 75 years. About 86.3% (n=44) patients were male and 13.7% (n=7) patients were female. Among the patients 52.9% were from low socioeconomic status and 47.1% patients were from middle socio-economic status.

Out of 51 patients, most (n=42, 82.4%) of the patients had the history of smoking. Among smoker majority (40.5%) of them reported to smoke 2 pack per day.

Table 1: Distribution of the patients according to socio-demographic variables (n=51)

Socio demographic Variables	n	%
Age		
≤40	2	3.9
41-50	7	13.7
51-60	22	43.1
61-70	15	29.4
≥ 71	5	9.8
Total	51	100.0
Mean ± SD (Min-Max)	59.73 ± 9.17	(38-75)
Sex		
Male	44	86.3
Female	7	13.7
Total	51	100.0
Socioeconomic Condition		
Lower	27	52.9
Middle	24	47.1
High	00	00
Total	51	100.0

Table 2: Distribution of the patients according to smoking history (n=51)

Smoking history	Frequency	Percent
Yes	42	82.4
No	9	17.6
Total	51	100.0
Smoking per among the smoker (n=41)		
1 pack per day	15	35.7
2 pack per day	17	40.5
3 pack per day	10	23.8
Total	42	100.0

Table 3: PAS stain in adenocarcinoma and adenosquamous carcinoma (n=13)

PAS stain	Frequency	Percent
Positive (Adenocarcinoma)	12	92.3%
Negative (Adenosquamous carcinoma)	1	7.7%
Total	13	100.0

Table 4: Distribution of the patients according to TTF-1 (n=51)

	Frequency	Percent
Positive	11	21.6
Negative	40	78.4
Total	51	100.0

Table 5: TTF-1 negative in squamous cell carcinoma (n=51)

Histological types			
TTF-1	Positive (Squamous cell carcinoma)	Negative (Other than SCC)	p-value*
Negative	35 (94.6)	5 (35.7)	0.453
Positive	2 (5.4)	9 (64.3)	
Total	37 (100.0)	14 (100.0)	

*McNemar test was done to measure the level of significance. The figure within parenthesis indicates in percentage.

Table 6: Validity test for identifying adenocarcinoma by positive TTF-1 immunostain

	Percentage	95% CI
Sensitivity	66.7	40.3-83.5
Specificity	92.3	84.2-97.5
PPV	72.7	43.9-91.1
NPV	90.0	82.1-95.1
Accuracy	86.3	73.8-94.2

PPV = Positive Predictive Value NPV = Negative Predictive Value
CI = Confidence Interval

Table 7: TTF-1 positive in adenocarcinoma (n=51)

Histological types			
TTF-1	Positive Adeno-carcinoma	Negative (Other than Adeno-carcinoma)	p-value*
Positive	8 (66.7)	3 (7.7)	0.999
Negative	4 (33.3)	36 (92.3)	
Total	12 (100.0)	39 (100.0)	

*McNemar test was done to measure the level of significance. The figure within parenthesis indicates in percentage.

Table 8: Validity test for identifying adenocarcinoma by positive TTF-1 immunostain.

	Percentage	95% CI
Sensitivity	66.7	40.3-83.5
Specificity	92.3	84.2-97.5
PPV	72.7	43.9-91.1
NPV	90.0	82.1-95.1
Accuracy	86.3	73.8-94.2

PPV = Positive Predictive Value NPV = Negative Predictive Value
CI = Confidence Interval

Previous history of lung disease

Among the 51 patients, (n=5, 9.8%) had a history of tuberculosis, and (n=3, 5.9%) had a history of COPD. Most of the patients (n=43, 84.3%) had no history of previous lung diseases.

Morphological types of tumor

Among 51 patients, the majority (37, 72.5%) of patients were squamous cell carcinoma followed by adenocarcinoma (12,23.5%). Only 1 (2%) case was adenosquamous carcinoma and another 1 (2%) case was small cell carcinoma by histopathological examination. It is shown in the following pie chart.

Evaluation of mucin by Periodic Acid Schiff Stain (PAS):

Table 3 shows that 12 patients (92.3%) with adenocarcinoma were positive for PAS stain. Single case of adenosquamous carcinoma (7.7%) showed a negative PAS stain. As per the research proposal, the PAS stain was not done in squamous cell carcinoma.

Table 4 shows the distribution of the patients according to TTF-1 immunostaining. Among the patients, 11 patients (21.6%) were positive, and 40 patients (78.4%) were negative by TTF-1 immunostaining.

Table 5 shows the distribution of the patients according to the negativity of TTF-1 immunostaining in squamous cell carcinoma. Among the 37 patients having squamous cell carcinoma, 94.6% of patients were negative and 5.4% of patients were positive by TTF-

1 immunostaining. On the other hand, among the 14 patients, 35.7% of patients were negative and 64.3% of patients were positive by TTF-1 immunostaining in other than squamous cell carcinoma. There was no statistically significant ($p>0.05$) difference observed between histopathological examination and TTF-1 immunostaining i.e. these two tests (histopathological examination and TTF-1 immunostaining) did not differ for the identification of squamous cell carcinoma.

Validity test to identify adenocarcinoma by TTF-1 immunostaining

Table 6 shows the validity test for identifying adenocarcinoma by positivity of TTF-1 immunostaining. The sensitivity (95% CI) was 66.7% (40.3-83.5), specificity (95% CI) was 92.3% (84.2-97.5), positive predictive value (95% CI) was 72.7% (43.9-91.1), negative predictive value (95% CI) was 90.0% (82.1-95.1) and accuracy (95% CI) was 86.3% (73.8-94.2). There were higher values all parameters. i.e. TTF-1 immunostaining could properly identify the adenocarcinoma. Table 7 shows the distribution of the

patients according to the positivity of TTF-1 immunostaining in adenocarcinoma. Among the 12 patients having adenocarcinoma, 66.7% of patients were positive and 33.3% of patients were negative by TTF-1 immunostaining. On the other hand, among the 39 patients not having adenocarcinoma, 7.7% of patients were positive and 92.3% of patients were negative by TTF-1 immunostaining. There was no statistically significant ($p>0.05$) difference observed between histopathological examination and TTF-1 immunostaining i.e. these two tests (histopathological examination and TTF-1 immunostaining) did not differ for the detection of adenocarcinoma. Table 8 shows the validity test for identifying adenocarcinoma by positivity of TTF-1 immunostaining. The sensitivity (95% CI) was 66.7% (40.3-83.5), specificity (95% CI) was 92.3% (84.2-97.5), positive predictive value (95% CI) was 72.7% (43.9-91.1), negative predictive value (95% CI) was 90.0% (82.1-95.1) and accuracy (95% CI) was 86.3% (73.8-94.2). There were higher values all parameters. i.e. TTF-1 immunostaining could properly identify the adenocarcinoma.

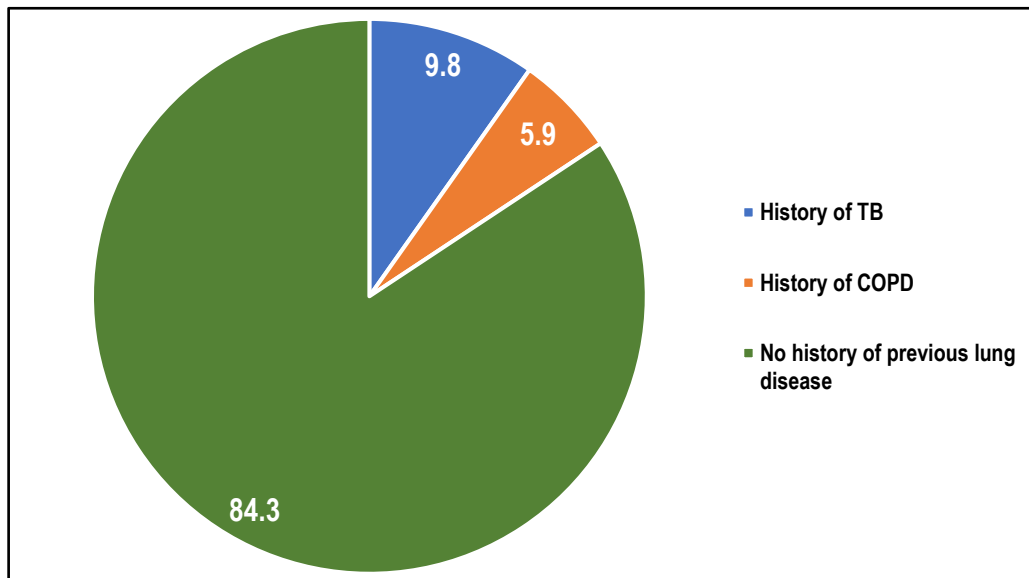


Figure 1: Distribution of the patients according to the past history of lung disease.

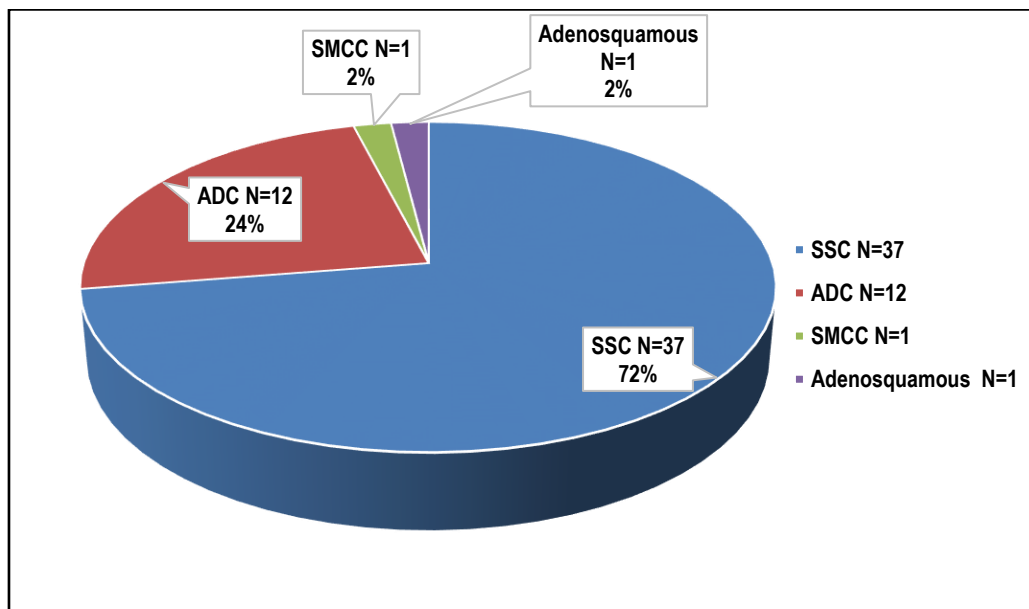


Figure 2: Pie chart of distribution of the patients according to histopathological classification (n=51)

DISCUSSION

In the current study, 51 patients with lung carcinoma were included and most of them were between 51 to 70 years of age. The mean (\pm SD) age of the patients was 59.73 (\pm 9.71) years with the minimum and maximum age of the patient were 38 years and 75 years respectively. Among the patients, 86.3% were male, and 13.7% were female. The male & female ratio was 6.29. Oktay et al. (2018) in their study of 200 patients reported that 78.5% were male and 21.5% were female patients¹². The higher incidence of lung carcinoma in the male may be due to personal habits such as smoking and more exposure to toxic agents.

The high prevalence of lung cancer in the lower socioeconomic groups may be due to the effect of poor education on health, lack of access to healthcare. No high socioeconomic groups were found in this study. Because they usually go to private clinics and corporate hospitals.

Smoking is one of the important risk factors for lung cancer. The observed patterns in lung cancer rates reflect the historical prevalence and variation in the trends of smoking among men and women. Incidence of the previously predominant squamous cell variety appears to be declining (although not universally), with a corresponding increase in adenocarcinoma (ADC) variety in both genders¹⁰. In the present study, most (82.4%) of the patients were smokers.

Among the patients, 9.8% of patients had a history of Tuberculosis, and 5.9% of patients had a history of COPD. Others did not give a history of TB and COPD due to inadequate treatment facilities for the poor people and lack of knowledge about the disease process. Among the patients 72.5% of patients had identified squamous cell carcinoma, 23.5% of patients had identified adenocarcinoma and only 2.0% of patients had identified as adenosquamous carcinoma and another 2.0% had small cell carcinoma.

All patients with adenocarcinoma were positive for PAS stain. One case of adenosquamous carcinoma showed a negative PAS stain. PAS stain was negative in a small biopsy. As per the research proposal, PAS stain was not done in Squamous cell carcinoma cases.

Tumors expressing positive TTF-1 staining were associated neither with demographics (i.e. gender and age) nor with disease characteristics (i.e. PS, TNM stage, or presence of metastasis)¹³. In the present study among the squamous cell carcinoma, 94.6% of patients were negative and 5.4% of patients were positive by TTF-1 immunostaining. On the other hand, 35.7% of patients were negative and 64.3% of patients were positive by TTF-1 immunostaining in other than squamous cell carcinoma patients. There was no statistically significant ($p > 0.05$) difference observed between histopathological classification and TTF-1 immunostaining i.e. these two tests (histopathological classification and TTF-1 immunostaining) did not differ for identification of squamous cell carcinoma.

The validity test was done for identifying squamous cell carcinoma by the negativity of TTF-1 immunostaining. The sensitivity (95% CI) was 94.6% (85.9-99.0), specificity (95% CI) was 64.3% (41.3-75.9), positive predictive value (95% CI) was 87.5% (79.4-91.6), negative predictive value (95% CI) was 81.8% (52.5-96.6) and accuracy (95% CI) was 86.3% (73.6-92.6). There were higher values for all parameters. i.e. TTF-1 immunostaining could properly identify the squamous cell carcinoma.

In the present study among the adenocarcinoma patients, 66.7% of patients were positive and 33.3% of patients were negative by TTF-1 immunostaining. On the other hand, 7.7% of patients were positive and 92.3% of patients were negative by TTF-1 immunostaining in other than adenocarcinoma patients. There was no statistically significant ($p > 0.05$) difference observed between histopathological examination and TTF-1 immunostaining i.e. these two tests (histopathological examination and TTF-1 immunostaining) did not differ for identification of adenocarcinoma.

In the present study the validity test for identifying adenocarcinoma by positivity of TTF-1 immunostaining showed the sensitivity (95% CI) was 66.7% (40.3-83.5), specificity (95% CI) was 92.3% (84.2-97.5), positive predictive value (95% CI) was 72.7% (43.9-91.1), negative predictive value (95% CI) was 90.0% (82.1-95.1) and accuracy (95% CI) was 86.3% (73.8-94.2). There were relatively higher values in all parameters. i.e. TTF-1 immunostaining could properly identify the adenocarcinoma. Jafarian et al. (2017) in their study reported that TTF-1 staining had 90% sensitivity for ADC and 95% sensitivity for SmCC but did not have good specificity to differentiate the two types¹⁴. Therefore, they recommended that it was not a good marker for the differential diagnosis of ADC and SCC.

CONCLUSIONS

TTF-1 was also found as a very sensitive and highly specific marker for the diagnosis of adenocarcinoma. So, the panel of TTF-1 may be effective for distinguishing undifferentiated pulmonary neoplasm in the bronchoscopic biopsy.

REFERENCES

1. Khoor A., Byrd-Gloster AL., Nicosia SV. Expression of thyroid transcription factor-1 in malignant pleural effusions. *Pathol Oncol Res* 2011; 17(2): 263–7.
2. Bohinski RJ., Di Lauro R., Whitsett JA. The lung-specific surfactant protein B gene promoter is a target for thyroid transcription factor 1 and hepatocyte nuclear factor 3, indicating common factors for organ-specific gene expression along the foregut axis. *Mol Cell Biol*; 1994; 14:5671–81.
3. Bejarano PA., Baughman RP., Biddinger PW, Miller MA, Fenoglio-Preiser C, Al-Kafaji B. Surfactant proteins and thyroid transcription factor-1 in pulmonary and breast carcinomas. *Mod Pathol* 1996; 9: 445–52.
4. Di Loreto, C., Di Lauro, V., Puglisi, F., Damante, N.G., Fabbro, D. and Beltrami, C.A. Immunocytochemical expression of tissue-specific transcription factor-1 in lung carcinoma. *Journal of clinical pathology* 1997; 50(1): 30-2.
5. Di Loreto, C., Puglisi, F., Di Lauro, V., Damante, G. and Beltrami, C.A. TTF-1 protein expression in pleural malignant mesotheliomas and adenocarcinomas of the lung. *Cancer letters* 1998; 124(1): 73-8.
6. Jonathan, L.H., Jack, L.P., Lisa, J.W., Geraldine, S.P. The value of thyroid transcription factor-1 in cytologic preparations as a marker for metastatic adenocarcinoma of lung origin. *Am J Clin Pathol* 2001; 116(4): 483-8.
7. Misch, D., Blum, T., Boch, C., Weiss, T., Crolow, C., Griff, S., et al. Value of thyroid transcription factor (TTF)-1 for diagnosis and prognosis of patients with locally advanced or metastatic small cell lung cancer. *Diagnostic pathology* 2015; 10(1): 21.

8. Micke, P., Botling, J., Mattsson, J.S.M., Planck, M., Tran, L., Vidarsdottir, H., et al. Mucin staining is of limited value in addition to basic immunohistochemical analyses in the diagnostics of non-small cell lung cancer. *Scientific Reports* 2019; 9(1): 1-10.
9. Kargi, A., Gurel, D. and Tuna, B. The diagnostic value of TTF-1, CK 5/6, and p63 immunostaining in the classification of lung carcinomas. *Applied Immunohistochemistry & Molecular Morphology* 2007; 15(4): 415-20.
10. Varma A., Patidar R., Dosi S., Malpani, G., Malukani, K., Jain, P.K., et al. Immunohistochemical Staining by TTF-1 and p63 Markers for Typing of Non-Small Cell Lung Carcinomas: A Three Year Study of A Tertiary Care Health Centre. *International Journal of Contemporary Medical Research* 2018; 5(3).
11. Argon, A., Nart, D. and Veral, A. The Value of Cytokeratin 5/6, p63, and Thyroid Transcription Factor-1 in Adenocarcinoma, Squamous Cell Carcinoma, and Non-Small-Cell Lung Cancer of the Lung. *Turkish Journal of Pathology* 2015; 31(2): 81-88.
12. Oktay, E., Oflazoglu, U., Varol, Y., Tanriverdi, O., Mermur, N., Arda, H.U., et al. The prognostic role of thyroid transcription factor-1 in lung adenocarcinoma. *Journal of Cancer Research and Therapeutics* 2018;14(12):1201.
13. Barlesi, F., Pinot, D., Legoffic, A., Doddoli, C., Chetaille, B., Torre, J.P. et al. Positive thyroid transcription factor 1 staining strongly correlates with survival of patients with adenocarcinoma of the lung". *British journal of cancer* 2005; 93(4):450-2.
14. Jafarian, A.H., Gharib, M., Roshan, N.M., Sherafatnia, S., Omid, A.A., and Bagheri, S. The diagnostic value of TTF-1, P63, HMWK, CK7, and CD56 immunostaining in the classification of lung Carcinoma. *Iranian Journal of pathology* 2017;12(3): 195.

Source of Support: Nil.

Conflict of Interest: None Declared.

Copyright: © the author(s) and publisher. IJMRP is an official publication of Ibn Sina Academy of Medieval Medicine & Sciences, registered in 2001 under Indian Trusts Act, 1882.

This is an open access article distributed under the terms of the Creative Commons Attribution Non-commercial License, which permits unrestricted non-commercial use, distribution, and reproduction in any medium, provided the original work is properly cited.

Cite this article as: Purabi Sarkar, Mohammad Zillur Rahman, Mohammad Ismail Hossain, Rumana Mahmud, Syeda Nabila Islam Juthee, Siddhartha Baowaly. Immunohistochemical Evaluation of Thyroid Transcription Factor (TTF-1) in Lung Carcinoma in Bangladeshi Patients. *Int J Med Res Prof.* 2021 Sept; 7(5): 009-14. DOI:10.21276/ijmrp.2021.7.5.003