

## A Rare Association of Hemoglobin J –Meerut Hemoglobinopathy with Gaucher's Disease

Samira Kumar Behera<sup>1</sup>, Shushruta Mohanty<sup>2\*</sup>, Fakir Charan Munda<sup>3</sup>, Saroj Ranjan Mohanty<sup>2</sup>

<sup>1</sup>Associate Professor, <sup>3</sup>Assistant Professor,  
Department of Pathology, SLN Medical College, Koraput, Odisha, India.

<sup>2</sup>Senior Resident,  
Department of Pathology, MKCG Medical College, Berhampur, Odisha, India.

### ABSTRACT

Hemoglobinopathies are one of the major public health problems that cause significant morbidity and mortality in the population. A plethora of variant haemoglobins have been described in the multi-ethnic Indian population. Detection of asymptomatic carriers by reliable laboratory methods is the cornerstone of prevention of this serious health problem. Appropriate laboratory tests are required for diagnosis and confirmation of these disorders. The identification of Hb variants by conventional techniques is often presumptive. HPLC offers the distinct advantage over classic Hb electrophoresis as it can more accurately identify and quantitate abnormal Hbs. Hb J Meerut is an infrequently found alpha globin variant that has been reported in various populations around the world. They are clinically silent and discovered accidentally. No case of Hb J alpha mutation with Gauchers disease has been reported earlier so far. Here we are reporting a rare variant of Hb J alpha mutation in association with Gaucher's disease that was

detected accidentally in a 5 yr male child by HPLC and USG guided splenic aspiration.

**Key words:** HB J Meerut, HPLC, Gauchers Disease.


### \*Correspondence to:

**Dr Shushruta Mohanty,**  
Senior Resident,  
Department of Pathology,  
MKCG MCH, Berhampur, Odisha, India.

### Article History:

Received: 05-05-2019, Revised: 02-06-2019, Accepted: 28-06-2019

### Access this article online

Website: <a href="http://www.ijmrp.com">www.ijmrp.com</a>	Quick Response code 
DOI: 10.21276/ijmrp.2019.5.4.021	

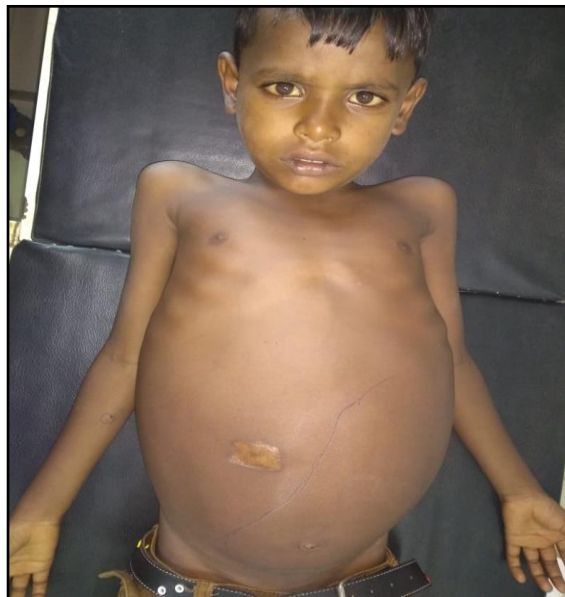### INTRODUCTION

Hb J is a heterogenous group of fast moving haemoglobin resulting from substitution of a negatively charged amino acid residue in either alpha, beta or gamma globin chains. Fast moving haemoglobin (FMH) predominantly is usually  $\alpha$  globin derived.<sup>1</sup> Haemoglobin J Meerut can be differentiated and identified solely on its retention time. In HPLC an abnormal peak in P3 window (>12%) with a retention time of 1.77 minutes is diagnostic of this variant. Hemoglobin J- Rajappen (alpha) 90 Lys to Thr is an alpha chain variant found in heterozygous state and usually presents as normal haematological picture. Hb J is a structural hemoglobinopathy. They are clinically silent carriers and mostly diagnosed accidentally during family and antenatal screening by alkaline gel electrophoresis.<sup>2</sup> FMH of J family revealed about 48 fast moving Hb J variants, some of them comprising of Hb J Meerut /Hb J Birmingham (alpha), Hb J-Bangkok (beta), Hb J- Baltimore (beta) and many more.

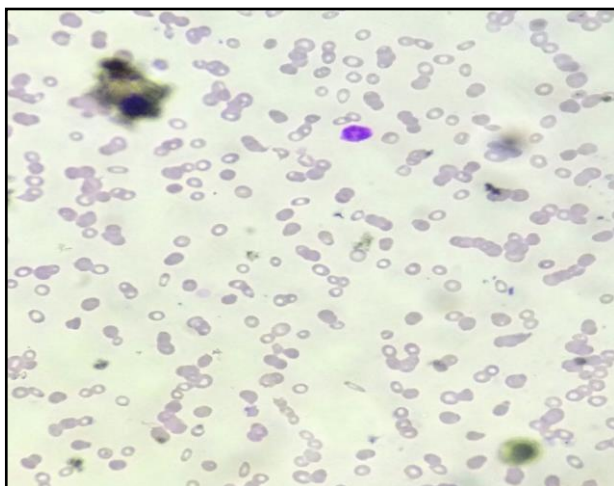
Gaucher's disease is an autosomal recessive lipid storage disorder, caused by mutations in the glucocerebrosidase gene 1q21. This defect leads to reduced enzyme activity with accumulation of glucosylceramide in the macrophages of the reticuloendothelial system. Three clinical subtypes of Gaucher's disease have been described on the basis of the absence (type I) or presence (types II and III) of a neurological component. Type I is more common, and is especially prevalent, among Ashkenazi Jews (predicted prevalence is about 1/850).<sup>3</sup> More than 200 mutations have been identified in the b-glucocerebrosidase gene, including point mutations, crossovers, and recombinations.

### CASE REPORT

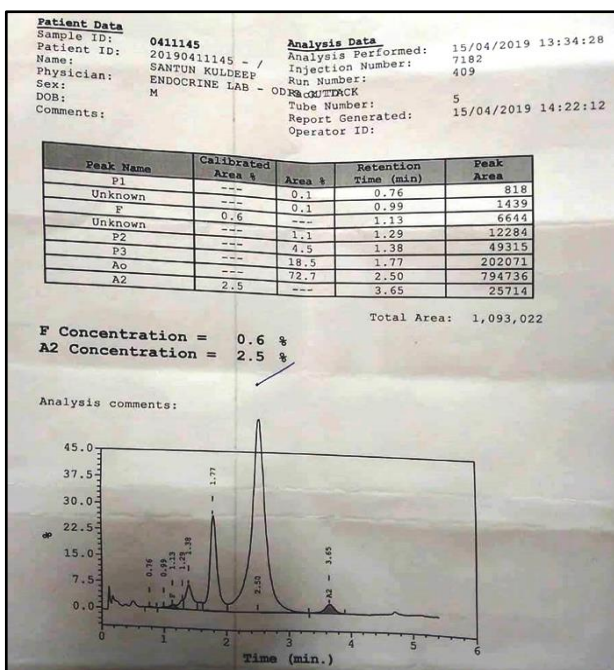
5 yr old male child presented with increase fatigue and abdominal distension since two years. On examination there was pallor +++, huge splenomegaly extending up to the right iliac fossa [Fig 1].



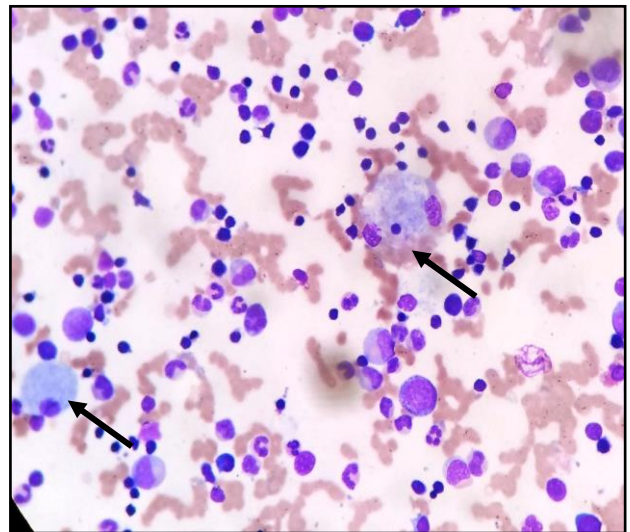
**Fig 1: Clinical pic showing huge splenomegaly extending upto rt iliac fossa**



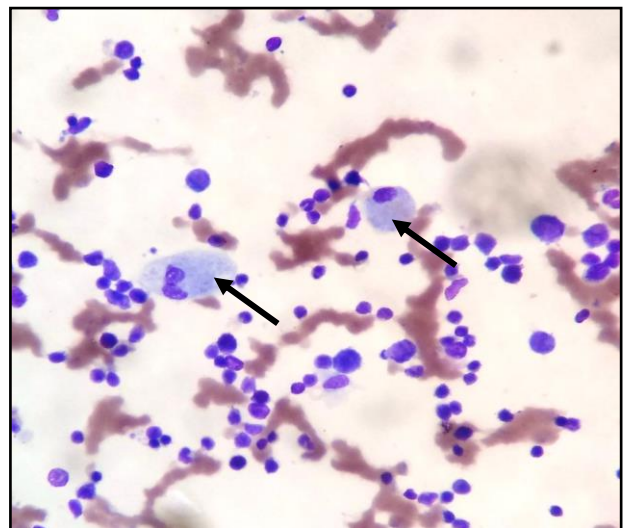
**Fig 2: 100x Peripheral smear Showing Pancytopenia.**



**Fig 3: HPLC showing an abnormal peak in P3 window (>12%) with a retention time of 1.77 minutes**



**Fig 4(a): LP100X-Bone marrow aspirate showing Gaucher cells admixed with good number of erythroid cells.**



**Fig 4 (b): Showing presence of Gaucher cells in BM aspirate (arrow).**

Routine blood investigations revealed a low Hb 7 gm%, and a haematocrit of 22%. Platelet was low around 90,000 and a lower TLC count of 2500 cells /mm<sup>3</sup>. MCV- 65.8fl, MCH was 20.5 pg with a normal RDW-Cv 17.1 %. Based on the findings of anemia (microcytic hypochromic) + leucopenia + thrombocytopenia CBC diagnosis of pancytopenia was given [Fig 2]. HPLC was done to rule out any haemoglobinopathy specially thalassemia revealed Hb F concentration of 0.6% and Hb A2 cons of 2.5%. There was a peak within the P3 [P3-18.5%] (Pic) with retention time of 1.77 mins confirming the case to be a rare haemoglobinopathy Hb J –Meerut [Fig 3]. But J-Meerut do not present with pancytopenia and splenomegaly. Bone marrow aspiration shows a hypercellular marrow with erythroid hyperplasia and scattered presence of Gaucher's cells (Pic) [Fig 4(a)(b)]. On request of Clinician USG guided splenic aspiration was done which showed numerous cells having abundant crumpled tissue paper type cytoplasm and small round nucleus (Classical Gaucher's cells)[Fig 5(a)(b)]. With the cumulation of the above findings we hereby report a case of Gauchers disease coexisting with a rare haemoglobinopathy Hb J-Meerut presenting with hypersplenism.



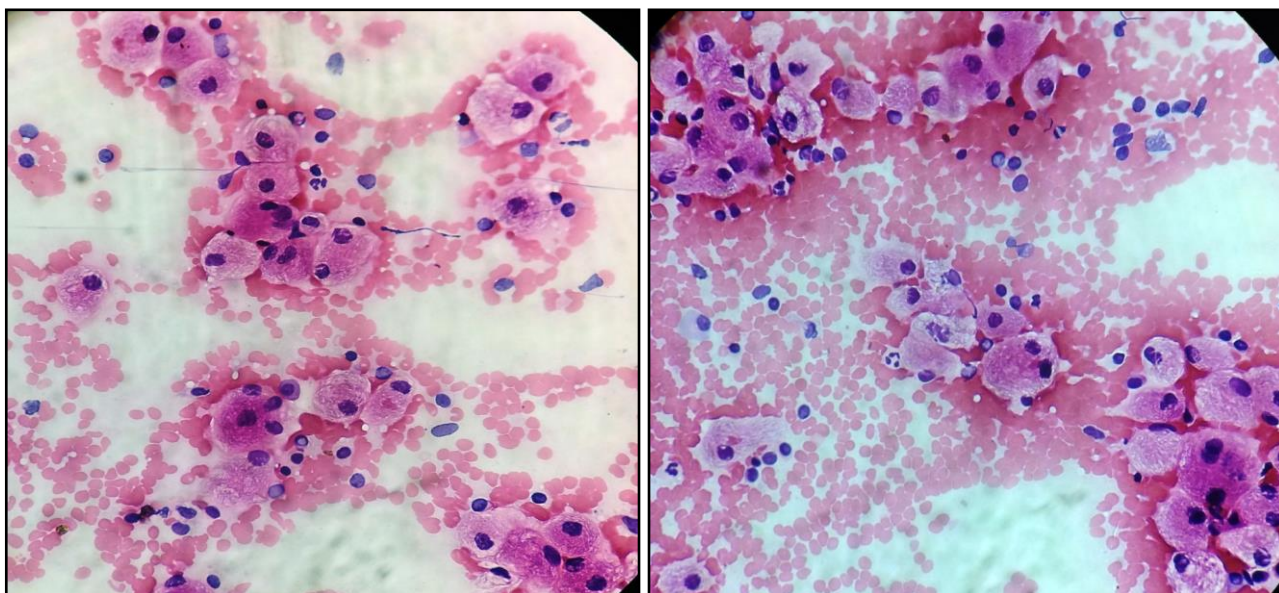


Fig 5 (a)(b): LP100X- USG guided Splenic aspirate showing presence of Gaucher cells.

## DISCUSSION

Haemoglobin J was first described in an African –American patient 1956 by Thorup et al in the year 1956.<sup>4</sup> Since then 50 variants of Hb J were described. Formation of Hb-J Meerut is due to a C>A mutation (GCG>GAG) at codon 120 of the alpha 1 or alpha 2 globin gene, changing the alanine to glutamic acid at residue 120 of the alpha chain.<sup>5-7</sup> The first case of Hb J Meerut was reported in two sisters from Meerut, Uttar Pradesh (India) and in two brothers from Bangladesh living in Bermingham, England. Subsequently the same abnormal haemoglobin was described in one Japanese and Turkish family.

The main etiology for this is the structural alteration of alpha ,beta or gamma globin chains varying from amino acid replacements, elongated chains, deletions, insertions, or both deletions and insertions. The clinically significant haemoglobinopathies are developed when there is abnormality of beta chain or alpha chain. The expression and the deletion of the disorder depends on the state of the zygosity. In heterozygous variants, the other normal allelic genes produces normal chains that may compensate for defective gene whereas in the homozygous state both allelic genes are affected that results in production of large amount of variants. Majority of Hb J do not have any affect on haematologic indices while some of the variants that have abnormal properties do affect the indices. Electrophoresis in conjunction with CE-HPLC serves as the best diagnostic modalities in diagnosing, quantitation and categorisation of haemoglobinopathies. Electrophoresis serves as the best screening modality for detecting haemoglobin variants whereas quantification of these variants are done best by the use of CE-HPLC from their characteristics RT's . In our case HPLC confirmed it as HbJ-Meerut type of haemoglobinopathy. Subsequently when child underwent splenic aspiration we got gaucher cells that were typically large 50-60 micro m in diameter with a small eccentric nucleus and fibrillary cytoplasm.

The pseudo-Gaucher cells look very similar to true Gaucher cells on light microscopic examination. Gaucher cells show diffuse iron

staining, whereas pseudo-Gaucher cells are generally negative. On electron microscopy, Gaucher cells contain tubular cytoplasmic inclusions, which are absent in pseudo-Gaucher cells that instead contain crystals. Pseudo-gaucher cells occur due to increased cell turnover, thereby leading to a relative enzyme deficiency.<sup>8</sup> Pseudo-Gaucher cells have been seen in a variety of conditions such as acute lymphoblastic leukemia, Hodgkin's disease, thalassemia, and multiple myeloma.<sup>9</sup> These are derived from increased load of leukocyte membrane derived glucosylceramide presented to macrophages under conditions of high cell turnover.<sup>8</sup>

## CONCLUSION

In our case HPLC played an indispensable role in validating diagnosis of Hb J-Meerut, a rare variant of abnormal haemoglobin and a definite diagnosis of Gaucher's disease was made by measuring the beta glucocerebrosidase activity in the presence of organomegaly, cytopenias and typical Gaucher cells in the splenic aspirate and bone marrow aspiration.

This case report highlights the co-existence of Gaucher disease and a rare variant of haemoglobinopathy Hb –J Meerut. Review of literatures depicted 7 cases of HB J –Meerut from India reported by U. Srinivas et al and a single case of Haemoglobin E haemoglobinopathy with association of Gaucher's disease reported by Chatterjee et al in 2013. Association of Hemoglobin J –Meerut with Gaucher's disease have not been reported earlier so far to the best of our knowledge and is the first case to be reported from Eastern India [Odisha].

## REFERENCES

1. Srinivas U, Mahapatra M, Pati H. Hb J Meerut, a fast moving haemoglobin: a study of seven cases from India and a review of literature. *Am J Hematol.* 2007;82:666-7.
2. Mondal SK, Mandal S. Prevalence of thalassemia and hemoglobinopathy in eastern India: a 10-year high-performance liquid chromatography study of 119,336 cases. *Asian J Transfusion Sci.* 2016;10(1):105.

3. Elstein D, Abrahamov A, Hadas-Halpern I, Zimran A (2001) Gaucher's disease: The Lancet 358:324–327.
4. Thorup OA, Itano HH, Wheby M, Leavell BS. Haemoglobin J. Science, 1956; 123 :889 -90.
5. Blackwell RQ, Boon WH, Wang CL, Weng MI, Liu CS. Haemoglobin J Meerut: alpha 120Ala->Glu Biochim Biophys Acta; 1974;351: 7-12.
6. Kamuzora H; Lehmann H, Griffiths KD, Mann JR, Raine DN. A new haemoglobin variant haemoglobin J Birmingham alpha 120 (H3) Ala ->Glu. Ann Clin Biochem, 1974;11:53-5.
7. Molchanova TP, Pobedimskaya DD, Huisman THJ. The differences in quantities of alpha2 and alpha 1 –globin gene variants in heterozygotes. Br J Haematol, 1994;88:300-6.
8. Carrington PA, Stevens RF, Lendon M (1992) Pseudo-Gaucher cells. J Clin Pathol 45:360.
9. Stewart AJ, Jones RDG (1999) Pseudo-Gaucher cells in myelodysplasia. J Clin Pathol 52:917–8.

**Source of Support:** Nil.

**Conflict of Interest:** None Declared.

**Copyright:** © the author(s) and publisher. IJMRP is an official publication of Ibn Sina Academy of Medieval Medicine & Sciences, registered in 2001 under Indian Trusts Act, 1882. This is an open access article distributed under the terms of the Creative Commons Attribution Non-commercial License, which permits unrestricted non-commercial use, distribution, and reproduction in any medium, provided the original work is properly cited.

**Cite this article as:** Samira Kumar Behera, Shushruta Mohanty, Fakir Charan Munda, Saroj Ranjan Mohanty. A Rare Association of Hemoglobin J –Meerut Hemoglobinopathy with Gaucher's Disease. Int J Med Res Prof. 2019 July; 5(4):92-95. DOI:10.21276/ijmrp.2019.5.4.021