

Cytological Study of Cervical Lymph Nodes with Clinico-Radiological Correlation in Adults

Vivek Singh¹, Deepti Arora^{2*}, Seema Awasthi³, Ashutosh Kumar³, Shyamoli Dutta⁴, Shruti Chandak⁵

¹PG Resident (Illrd Year), ^{2*}Assistant Professor, ³Professor, ⁴Professor & Head,
Department of Pathology, Teerthanker Mahaveer Medical College & Research Centre, Moradabad, UP, India.

⁵Professor,
Department of Radiology, Teerthanker Mahaveer Medical College & Research Centre, Moradabad, UP, India.

ABSTRACT

Objective: The spectrum of lesions diagnosed by fine needle aspiration cytology with routine & special stains and its correlation with radiological findings.

Materials & Methods: The study is performed on a total of hundred (100) patients over duration from February 2017 to September 2018. The data was collected in cytopathology section of TMMC & RC from the patients referred from OPDs or was admitted through the period of study.

Results: Among 100 FNAC cases, 36(36%) had Necrotizing Granulomatous Lymphadenitis, 23(23%) had Granulomatous Lymphadenitis, 20(20%) had Reactive Lymphadenopathy, 6% had suppurative lymphadenitis & 2% had Necrotic Lymph node, 10(10%) had Metastatic Squamous cell carcinoma, 2(2%) had Hodgkin Lymphoma, 1(1%) had Non – Hodgkin Lymphoma.

Conclusion: Our study concluded that FNAC is a minimally invasive, cost effective and rapid diagnostic tool. When used in

conjunction with radiology for the diagnosis of lymphadenopathy FNAC can be a cost effective method.

Keywords: Fine Needle Aspiration Cytology, Lymphadenitis, Carcinoma, Lymphoma.


***Correspondence to:**

Dr. Deepti Arora,
Assistant Professor,
Department of Pathology,
TMMC & RC, Moradabad, UP, India.

Article History:

Received: 02-04-2019, **Revised:** 29-04-2019, **Accepted:** 09-05-2019

Access this article online

Website: www.ijmrp.com	Quick Response code 
DOI: 10.21276/ijmrp.2019.5.3.007	

INTRODUCTION

Lymph nodes are natural defence system. Lymph nodes in cervical region are prone to various pathological entities like infection, inflammation & tumours.¹ The causes of cervical lymphadenopathy are varied, and may be inflammatory, degenerative, or neoplastic.² Cervical lymph nodes upto the age of 12 years upto 1cm in size in children are palpable but this may not signify any disease.³ Tubercular lymphadenitis is the most frequent cause of cervical lymphadenopathy in developing nations like India.⁴ Radiologically lymph nodes show calcifications, variability in size & shape, having cystic, solid or mixed component & variable echogenicity. Hence this study was planned to study the spectrum of lesions of cervical lymph nodes on FNAC & to correlate it with its radiological findings.

Persistent enlargement of the lymph node necessitates detailed investigations to reveal an underlying pathology.⁵ Fine needle aspiration cytology is a well-established method for the early diagnosis of disease of the lymph nodes.⁶ For the rapid diagnosis of cervical lymphadenopathy FNAC is a simple & accurate procedure with minimum trauma & low cost.

MATERIALS & METHODS

The current study is a prospective study performed on a total of hundred (100) patients over duration from February 2017 to September 2018. The data was collected in cytopathology section of TMMC & RC from the patients referred from OPDs or indoor during the period of study.

The clinical data includes patient's lab number, age, sex, site of lymphadenopathy, size & duration. Radiological examination was performed & findings were noted down. After explaining the procedure written consent was taken. The swelling aspiration was taken by pulling the piston moving back & forth with the help of standard disposable 22 gauge needles. Smears were air dried & wet fixed. Dried smears were stained by May Grunwald Giemsa & wet fixed smears were stained by Hematoxylin and eosin and special stains were applied wherever needed. FNAC aspirates were examined.

These findings were correlated with the radiology. Cases where the size of lymph node was too small were subjected to USG guided aspiration.

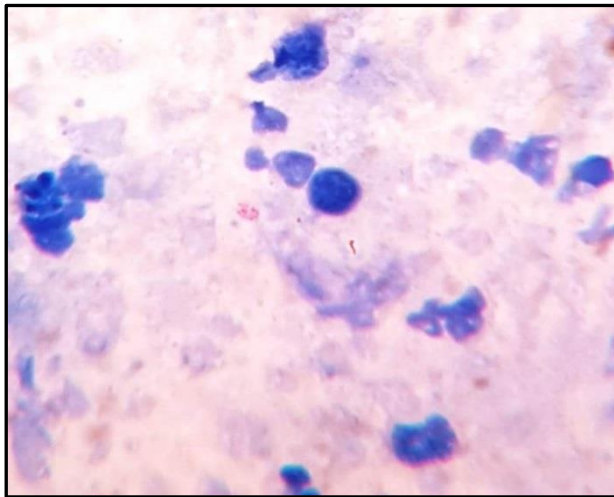


Fig 1: Smear Showing Acid Fast Bacilli On (ZN, 1000X).

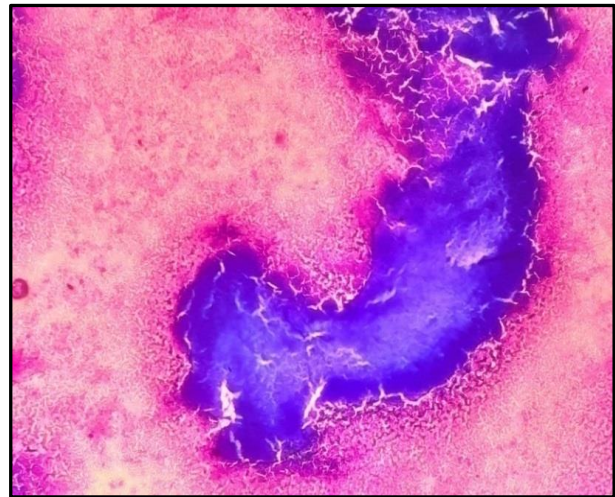


Fig 2: Smear Showing Necrosis (Giemsa, 400X)

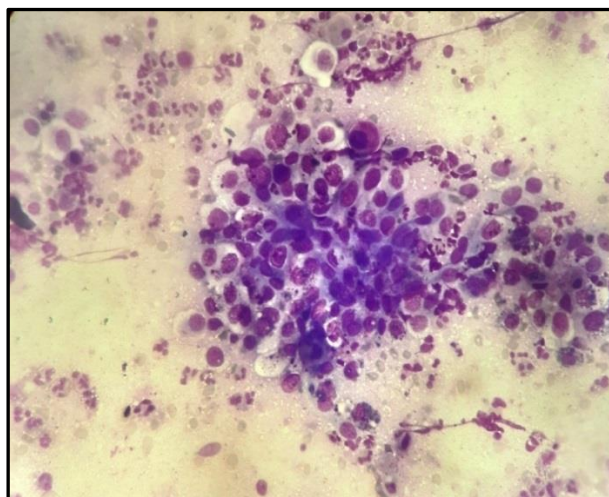


Fig3: Metastatic Squamous Cell Carcinoma (Giemsa, 400X).

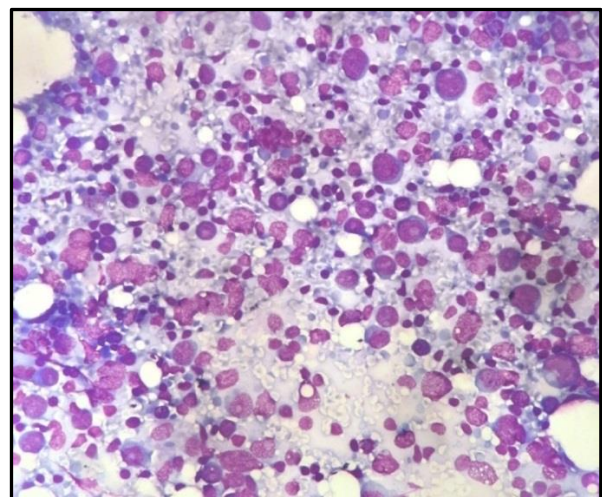


Fig 4: Hodgkin's Lymphoma Giemsa, 400X).

Table 1: Showing distribution of cases according to final diagnosis on cytology.

FNAC	Frequency	Percentage
Granulomatous Lymphadenitis	23	23.0%
Necrotic Lymphadenitis	2	2.0%
Necrotizing Granulomatous Lymphadenitis	36	36.0%
Reactive lymphadenopathy	20	20.0%
Suppurative lymphadenitis	6	6.0%
Primary Malignancy		
HL	1	1.0%
NHL	2	2.0%
Secondary Malignancy		
Metastatic SCC	10	10.0%
Total	100	100.0%

Table 2: Showing distribution of cases into different categories radiologically

Radiological diagnosis	Frequency	Percentage
Infective etiology	6	6.0%
Reactive Lymphadenopathy	36	36.0%
Tubercular Lymphadenitis	38	38.0%
Necrotic lymphadenitis	16	16.0%
Lymphomatous Lymphadenopathy	3	3.0%
Metastatic lymphadenopathy	1	1.0%
Total	100	100.0%

Table 3: Showing Cytological & Radiological Correlation

Radiological Diagnosis	Cytological Diagnosis								Total
	Suppurative Lesion	R.Lap	G.Lan	N.G.Lan	Necrotic Lan	Metastatic SCC	NHL	HL	
Infective Etiology (N=6)	6	-	-	-	-	-	-	-	6
R. Lan (N=36)	-	20	13	3	-	-	-	-	36
Tubercular Lan (N=38)	-	-	10	28	-	-	-	-	38
Necrotic L.N (N=16)	-	-	-	5	2	9	-	-	16
Lymphomatous Lap (N=3)	-	-	-	-	-	-	2	1	3
Metastatic Lap (N=1)	-	-	-	-	-	1	-	-	1
Total(N=100)	6	20	23	36	2	10	2	1	100

RESULTS

The study population consisted of 100 cases out of which 55 were males and 45 were females, 44(44.0%) were from 18-25 years age group, 32(32.0%) from 26-35 years and 24 (24.0%) subjects from above 35 years age group. The duration of lesions was found to be 0-1 month among 33 (33.0%), 1-3 months among 37 (37.0%), 3-6 months among 20 (20.0%) and above 6 months among 10 (10.0%) subjects. The size of lesions was less than 3 cm among 79 (79.0%) and 3-6 cm among 21 (21.0%) subjects. Majority of the patients showed granulomatous lymphadenitis (n=59). Among these patients 23 presented with granulomatous lymphadenitis & 36 showed features of necrosis i.e necrotizing granulomatous lymphadenitis. 13 cases showed malignant lesions i.e 3 primary & 10 secondary.

On Radiological diagnosis, Infective etiology was found among 6 (6.0%), Reactive Lymphadenopathy among 36 (36.0%), Tubercular lymphadenitis among 38 (38.0%), Necrotic lymphadenitis among 16 (16.0%), Lymphomatous lymphadenopathy among 3(3.0%) & Metastatic lymphadenopathy among 1(1%) cases.

In the present study, we compared cytological findings of 100 cases with their respective radiological findings. Out of 100 cases diagnosed cytologically, 75 cases were found to be in correlation with radiological findings, however 25 cases were found to be in discordance.

Among these 25 cases of discordance 16 cases which were diagnosed reactive on radiology found to be granulomatous and necrotizing granulomatous 13 cases and 3 cases respectively on cytology, 9 cases which were found to be necrotic on radiology was turned out to be metastatic on cytology which further changed the diagnosis, management and prognosis of disease.

DISCUSSION

FNAC has been recommended as a first line screening method in suspected malignancy.⁷ Since FNAC is a simple procedure with minimum trauma & low cost with no complications therefore it plays an important role in the diagnosis of primary or the secondary malignancies especially in developing nations like India.⁸⁻¹⁰ even in cases where malignancy is not suspected clinically & when lymph nodes are undetectable clinically the use of special investigations like USG guided FNAC is useful to detect malignancy.¹¹ In our study primary sites of lymphadenopathy in every lymph node faction correlated with previous comparable studies.¹²⁻¹⁴ In our study population maximum cases belonged to 18-25 years age group (n=44) followed by 26-35 years (n=32) and 35-45 years (n=24). This is comparable to the study by Jyoti P. et al.¹⁵ Bhavani et al.¹⁶ Swapnil More et al.¹⁷ who also had maximum number of cases in similar age groups.

Gender ratio is analogous to Sravani P et al.¹⁸ Jyoti P et al.¹⁵ in which males were more affected than females. However this is in contrast with Priya R et al.¹⁹ reported in the South Coastal Region of India, Swapnil More et al.¹⁷ Attullah et al.²⁰ where females showed the higher frequency of cervical lymphadenopathy.

In present study, 13% (13) lesions were neoplastic and 87% (87) were non-neoplastic, of which, 20.0%(20) were Reactive lymphadenopathy, 6%(6) cases were Suppurative lymphadenitis, 23.0%(23) showed Granulomatous Lymphadenitis, 2.0%(2) were diagnosed as Necrotic Lymphadenitis and 36.0%(36) showed Necrotizing Granulomatous Lymphadenitis. These findings are similar to Ahmad et al.²¹ & Jyoti P et al.¹⁵ however the present study is in contrast with Chawla et al.²², Qadri et al.²³ & Priya R. et al.¹⁹ where reactive lymphadenitis was the most common cause of cervical lymphadenopathy.

Table 4: Showing Comparison of various lesions with other studies.

Study	Non- Neoplastic %	Neoplastic %	Most Common lesion	No. of cases %
Ahmad et al.	89	11	Tubercular Lymphadenitis	50
Chawla et al.	79.7	17	Reactive lymphadenitis	41.7
Qadri et al.	54.9	45.0	Reactive lymphadenitis	39.4
Priya R et al.	75.1	21.8	Reactive lymphadenitis	34.64
Jyoti P et al.	88.02	11.75	Tubercular lymphadenitis	55.55
Present Study	87	13	Tubercular lymphadenitis	36

Table 5: Showing Comparison of malignant lymphadenopathy with other studies

Study	Primary Malignancy	Secondary Malignancy	Total malignancies (no/ total cases)
	%	%	
Ahmad et al.	1	9	10/100
Ameya Buli et al.	3.27	3.65	74/1067
Arul p et al.	3	9.5	62/497
Jyoti P.	1.5	10.5	140/1195
Present study	3	10	13/100

Table 6: Comparison of statistical distribution of present study with other studies

Study	Sensitivity	Specificity	PPV	NPV	DA
Nesreen et al.	90.9%	67.2%	82.6%	81.3%	82.2%
Priya R et al.	97%	95%	97%	95%	96%
Arul P. et al.	82.4%	98.1%	95.2%	90.3%	96.2%
Present Study	85%	70%	82.50%	75%	78.5%

The present study is similar in findings with the study by Dukare et al.²⁴, Shakera N. Baji et al.²⁵, Maheshwari et al.²⁶, Sachin A. Badge et al.²⁷, Deepshikha Dave et al.²⁸, Malhotra AS et al.²⁹ also showed similar results with tubercular lymphadenitis as most common followed by reactive lymphadenopathy and metastatic lesions. This was contrasting to the study by Kalpana Chandra et al.³⁰ in which Metastatic carcinomas (93) was most common followed by Reactive lymphadenopathy (82) and granulomatous lymphadenitis (67) and Sheema Sheikh et al.³¹ in which reactive lymphadenopathy(447) was the most common (91) diagnosis followed by metastatic tumors.

In present study malignant lymphadenopathy was seen in 13% cases among which secondary malignancy 10 (10%) was more common than primary malignancy 3(3%) which is similar to Ahmad et al.²¹, Ameya Buli et al.³², Arul P et al.³³, Jyoti P et al.¹⁵ Among the secondary malignancy metastatic squamous cell carcinoma was more common which is in contrast with Ghartimagar et al.³⁴ where Adenocarcinoma was predominant malignant lymphadenopathy followed by metastatic SCC and comparable to the study by Baji et al.²⁵ and Sravani P et al.¹⁸ where metastatic SCC was also the predominant malignant lymphadenopathy seen.

In our study, Sensitivity for FNAC to diagnose cervical lesion is 85.00%, Specificity 70.00%, Positive Predictive Value 82.50%, Negative Predictive Value 75.00% and Accuracy as 78.5%. This is comparable to the study by Nesreen et al.³⁵ overall sensitivity of FNAC was 90.9%, specificity 67.2%, positive predictive value 82.6%, negative predictive value 81.3% & the overall diagnostic accuracy was 82.2%, Priya R et al.¹⁹ the sensitivity, specificity & diagnostic accuracy of FNAC was 97%, 95% and 96% respectively and Arul P. et al.³³ sensitivity, specificity, accuracy, positive predictive value, and negative predictive values of FNAC were 82.4%, 98.1%, 95.2%, 90.3%, and 96.2%.

CONCLUSION

FNAC is a minimally invasive, cost effective and rapid diagnostic tool. It has a very high degree of patient acceptance because it does not cause any unsightly scars, inconvenient incision lines. It is an invaluable sensitive tool for the detection of malignant neck lesions and equally effective in the diagnosis of non-malignant

lesions. FNAC when used in conjunction with radiology for the diagnosis of lymphadenopathy FNAC can be a cost effective method. If the clinically suspected disease do not correlates with FNAC findings then appropriate diagnostic work-up for the disease is performed. It should be noted that FNAC negative findings or results does not rule out malignancy. And for the better results there should be a closed communication between a referring doctor & cytologist. The present study demonstrates that FNAC is a rapid, safe and valuable tool in the diagnosis of cervical lymphadenopathy.

The accuracy and success of FNAC depends mostly on some elementary factors like adequate aspirate from representative site and it's proper processing for evaluation. The increasing use of more sophisticated techniques has improved the potential to make precise specific diagnoses.

REFERENCES

- Eisenmenger, Wiggins RH. Imaging of head and neck lymph nodes. Radiologic clinics of North America. 2015; 53(1):115–32.
- Terézhalmy GT, Huber MA, Jones AC. Physical evaluation in dental practice. Ames, Iowa Wiley-Blackwell. 2009; pp. 120–23, 160, 172.
- Hupp JR, Ellis E, Tucker MR. Contemporary oral and maxillofacial surgery (5th ed.). St. Louis, M. Mosby Elsevier.2008; pp. 428–30.
- Sudipta Pandit et al. Cervical Lymphadenopathy—Pitfalls of Blind Antitubercular Treatment. J Health Popul Nutr. 2014 Mar; 32(1): 155–59.
- Melkundi RS, Melkundi S et al. Clinicopathological Study Of Cervical Lymphadenopathy. Int J Otorhinolaryngol Head Neck Surg 2017;3:244-9.
- Ghazala Mehdi et al. Cytological evaluation of enlarged lymph nodes in metastatic disease: A hospital-based assessment. Clinical cancer investigation control. Year. 2015; 4(2): 152-57.
- Coyne JD, Banerjee SS, Menasche LP, Mene A. Granulomatous lymphadenitis associated with metastatic malignant melanoma. Histopathol. 1996; 28(5):470-2.
- Bagwan IN, Kane SV, Chinoy RF. Cytologic evaluation of the enlarged neck node: FNAC utility in metastatic neck disease. Int J Pathol 2007;6:2.

9. Alam K, Khan A, Siddiqui F, Jain A, Haider N, Maheshwari V. Fine needle aspiration cytology (FNAC): A handy tool for metastatic lymphadenopathy. *Int J Pathol* 2010;10:2.
10. Khajuria R, Goswami KC, Singh K, Dubey VK. Pattern of lymphadenopathy on fine needle aspiration cytology in Jammu. *JK Sci* 2006;8:157-9.
11. Hoft S, Muhle C, Brenner W, Sprenger E, Maune S. Fine-needle aspiration cytology of the sentinel lymph node in head and neck cancer. *J Nucl Med.* 2002;43:1585–90.
12. Alam K, Khan A, Siddiqui F, Jain A, Haider N, Maheshwari V. Fine needle aspiration cytology (FNAC): A handy tool for metastatic lymphadenopathy. *Int J Pathol.* 2010;10:2.
13. Sinha SK, Basu K, Bhattacharya A, Banerjee U, Banerjee D. Aspiration cytodiagnosis of metastatic lesions with special reference to primary sites. *J Cytol.* 2003;20:16–8.
14. Gupta N, Rajwansi A, Srinivasan R, Nijwahan R. Pathology of supraclavicular lymphadenopathy in Chandigarh, north India: An audit of 200 cases diagnosed by fine needle aspiration. *Cytopathology.* 2006;17:94–6.
15. Jyoti Priyadarshini Shrivastava. Role of FNAC in the evaluation of cervical lymph nodes: A hospital based study. *Journal of Evolution of Medical and Dental Sciences* 2015; 4(55); Page: 9643-48, DOI: 10.14260/jemds/2015/1391.
16. C. Bhavani et al. Role of FNAC in the Diagnosis of Cervical Lymphadenopathy. *International Journal of Medical Research and Review;* 2-14; 2(06).
17. Swapnil More et al. FNAC of cervical lymph nodes. *IJWR:* 2(1), August 2012.
18. Sravani P et al. Fine needle aspiration a simple and handy tool to diagnose malignant lymphadenopathy? *Int J Res Med Sci.* 2017 Sep;5(9):3949-53.
19. Priya R et al. Fine Needle Aspiration Cytology of Cervical Lymphadenopathy: Is There Anything Different At South Coastal Region of India. *Annals of Pathology and Laboratory Medicine,* July-August, 2017. 4(4).
20. Attaullah M, Shah W, Pervez SN, Khan S, Jehan S, Rahim S. Cytomorphological pattern of superficial lymphadenopathy. *Gomal J Med Sci* 2012; 12:197-200.
21. Shamshad Ahmad et al. Study of Fine Needle Aspiration Cytology in Lymphadenopathy with Special Reference to Acid-fast Staining in Cases of Tuberculosis. *JK Science;* January-March 2005; 7(1).
22. Nitin Chawla et al. FNAC of Lymph Node Disorders. *Indian Medical Gazette,* 312 August 2012.
23. Qadri SK, Hamdani NH, Besina S, Makhdoomi R, Rasool R, et al. Cytological Study of Cervical Lymphadenopathy in a Tertiary Care Institution from Kashmir Valley, India. *J Cytol Histol* 7: 418. doi:10.4172/2157-7099.1000418.2016.
24. Dukare S. R et al. Fine Needle Aspiration Cytology of cervical lymphadenopathy A study of 510 cases. *Asian Journal of Science and Technology;* September, 2014; 5(9), 537-40.
25. Bajji SN, Anand V, Sharma R, Deore KS, Chokshi M. Analysis of FNAC of cervical lymph nodes: Experience over a two years period. *Int J Med Sci Public Health* 2014;3:607-09.
26. Abhishek Maheshwari, Rajesh Kumar Padhy, Bijoy Kumar Dash. A Clinicopathological Study of Cervical Lymphadenopathy. *Journal of Evolution of Medical and Dental Sciences* 2015; 4(20), March 09. Page: 3497-3507, DOI:10.14260/jemds/2015/504.
27. Badge SA, Ovhal AG, Azad K, Meshram AT. Study of fine-needle aspiration cytology of lymph node in rural area of Bastar District, Chhattisgarh. *Med J DY Patil Univ* 2017;10:143-8.
28. Deepshikha Dave. Role of FNAC in the Diagnosis of Cervical Lymphadenopathy. *IOSR Journal of Dental and Medical Sciences (IOSR-JDMS)* Volume 15, Issue 10 Ver. XII (October. 2016), PP 48-54.
29. Malhotra AS, Lahori M, Nigam A, Khajuria A. Profile of lymphadenopathy: An institutional based cytomorphological study. *Int J App Basic Med Res* 2017;7:100-3.
30. Kalpana Chandra, Praveen Kumar, Surabhi Pandey. Cytomorphological Evaluation of Lymphadenopathy on Fine Needle Aspiration Cytology: A Hospital Based Retrospective Study. *Journal of Evolution of Medical and Dental Sciences* 2014; Vol. 3, Issue 51, October 09; Page: 11929-11937, DOI: 10.14260/jemds/2014/3574.
31. Sheema Sheikh et al. Cytological pattern of head and neck lymphadenopathy: A study at a tertiary care centre. *International Journal of Current Research* Vol. 7, Issue, 08, pp.19706-10, August, 2015.
32. Gemechu Ameya Buli et al. Cytologic patterns of lymph node diseases in Hawassa University Referral Hospital, Southern Ethiopia. *Journal of Coastal Life Medicine* 2015; 3(5): 395-397.
33. Arul P, Masilamani S, Akshatha C. Diagnostic efficacy of fine-needle aspiration cytology in the evaluation of cervical lymphadenopathy. *J Sci Soc* 2016;43:117-21.
34. Ghartimagar D et al. Utility of fine needle aspiration cytology in metastatic lymph nodes. *Journal of Pathology of Nepal* (2011) Vol. 1, 92-95.
35. Nesreen Hafez et al. Reliability of fine needle aspiration cytology (FNAC) as a diagnostic tool in cases of cervical lymphadenopathy. *Journal of the Egyptian National Cancer Institute* (2011) 23, 105–14.

Source of Support: Nil. **Conflict of Interest:** None Declared.

Copyright: © the author(s) and publisher. IJMRP is an official publication of Ibn Sina Academy of Medieval Medicine & Sciences, registered in 2001 under Indian Trusts Act, 1882. This is an open access article distributed under the terms of the Creative Commons Attribution Non-commercial License, which permits unrestricted non-commercial use, distribution, and reproduction in any medium, provided the original work is properly cited.

Cite this article as: Vivek Singh, Deepti Arora, Seema Awasthi, Ashutosh Kumar, Shyamoli Dutta, Shruti Chandak. Cytological Study of Cervical Lymph Nodes with Clinico-Radiological Correlation in Adults. *Int J Med Res Prof.* 2019 May; 5(3):35-39. DOI:10.21276/ijmrp.2019.5.3.007