

# Analysis of Lesions of Nasal Cavity and Para Nasal Sinuses at a Tertiary Care Hospital: A Histopathological Study

Amulya Singh<sup>1</sup>, Neelam Harit<sup>2\*</sup>

<sup>1</sup>Assistant Professor, Department of Pathology,  
Saraswathi Institute of Medical Sciences, Hapur Road, Anwarpur, Uttar Pradesh, India.

<sup>2\*</sup>Assistant Professor, Department of Pathology,  
Krishna Mohan Medical College and Hospital, Mathura, Uttar Pradesh, India.

## ABSTRACT

**Background:** The nasal cavity, nasopharynx and paranasal sinuses form functional unit of nose. The present study was conducted to assess lesions of nasal cavity and paranasal sinuses histopathologically.

**Materials & Methods:** The present study was conducted on 76 biopsies. All the biopsies were fixed with 10% buffered formalin. Haematoxylin and eosin staining was done.

**Results:** Out of 76 biopsies, 34 were of males and 40 were of females. Non-neoplastic lesions were 48 and neoplastic lesions were 28. The difference was significant ( $P < 0.05$ ). Fungal infection was seen in 10, inflammatory polyp was 24, Nasal Glioma were 8 and Rhinosporidiosis was 6. Neoplastic lesions were benign in 18 cases and malignant in 10. Benign neoplastic lesions were inverted papilloma (8), schwannoma (4), angiofibroma (4) and capillary hemangioma (2). Malignant neoplastic lesions were squamous cell carcinoma (4), basal cell carcinoma (2), neuroblastoma (1), round cell tumor (1), plasmacytoma (1) and hemangiopericytoma (1). The difference was significant ( $P < 0.05$ ).

**Conclusion:** Most common lesions were fungal infection, inflammatory polyp, Nasal Glioma and Rhinosporidiosis.

**Key words:** Neoplastic, Nose, Fungal.


## \*Correspondence to:

**Dr. Neelam Harit,**  
Assistant Professor,  
Department of Pathology,  
Krishna Mohan Medical College and Hospital,  
Mathura, Uttar Pradesh, India.

## Article History:

Received: 09-02-2019, Revised: 05-03-2019, Accepted: 26-03-2019

## Access this article online

Website: <a href="http://www.ijmrp.com">www.ijmrp.com</a>	Quick Response code 
DOI: 10.21276/ijmrp.2019.5.2.067	

## INTRODUCTION

The nasal cavity, nasopharynx and paranasal sinuses form functional unit of nose and is principally involved in filtering, humidifying and adjusting the temperature of inspired air. As the nose occupies a prominent anatomical position on the face, early diagnosis and treatment of any scarring or ulcerative lesion is imperative.<sup>1</sup> Diseases of the nasal cavity include viral, bacterial and fungal infections, nasal cavity tumors as well as inflammations of the nasal mucosa. Deviated nasal septum, common cold, nasal polyp, nosebleed, rhinitis and broken nose are common lesions affecting nasal cavity. Nasal polyps are the most common cause of nasal obstruction. The most common causes are allergy, asthma and infections.<sup>2</sup>

Polypoidal mass in the nose is a very common lesion encountered in clinical practice. It may be due to the most frequently occurring simple nasal polyp or polypoidal lesions due to a variety of other pathologic entity ranging from infective granulomatous diseases to polypoid neoplasm including malignant ones. Benign lesions of nasal cavity (NC) and paranasal sinuses (PNS) are common. Malignant lesions in nasal cavity, paranasal sinuses and nasopharynx constitute approximately 1% of all the malignant

tumours. A wide range of variation in histopathological types and grades of malignancies has led the emergence of studying their clinical and pathological aspects. The exact nature of the lesion eliminates the confusion and strengthens the diagnosis. Thus by knowing the diagnosis, exact treatment can be given to the patient. It is beneficial for both clinician and patient.<sup>3</sup> The present study was conducted to assess lesions of nasal cavity and paranasal sinuses histopathologically.

## MATERIALS AND METHODS

The present study was conducted in Department of Pathology, Saraswathi Institute of Medical Sciences, Hapur Road, Anwarpur, Uttar Pradesh, India. It comprised of 76 tissues obtained in the department. The study protocol was approved from institutional ethical committee. Data such as name, age, gender, chief complaint, clinical and radio graphical findings etc. were retrieved from OPD record. All the biopsies received were fixed with 10% buffered formalin. Haematoxylin and eosin staining was done. Results thus obtained were tabulated and subjected to statistical analysis. P value less than 0.05 was considered significant.

**Table I: Distribution of patients**

Total- 76		
Gender	Males	Females
Number	34	40

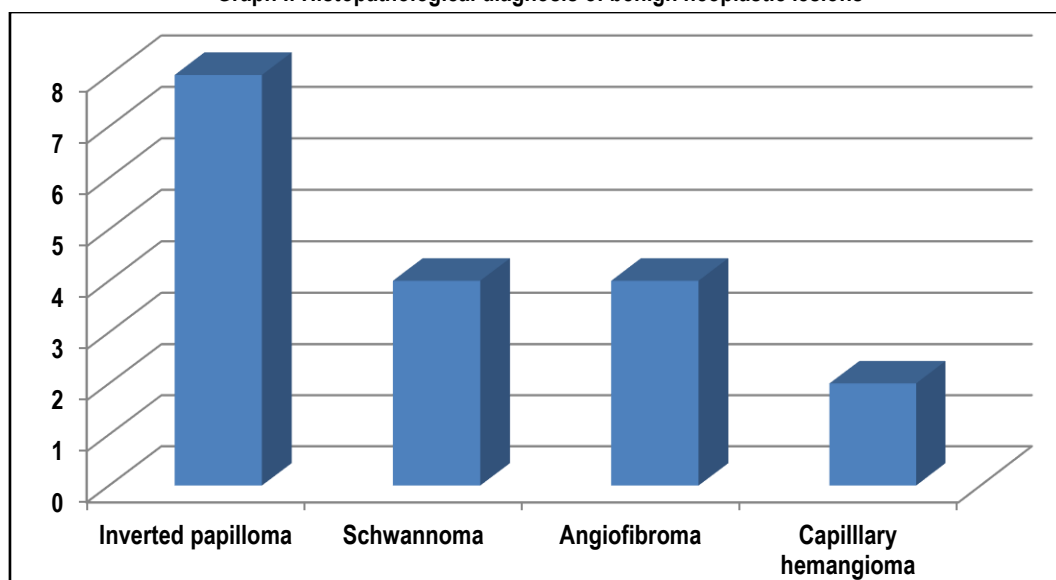
**Table II: Different lesions of PNS**

Non neoplastic lesion	Neoplastic lesion	P value
48	28	0.02

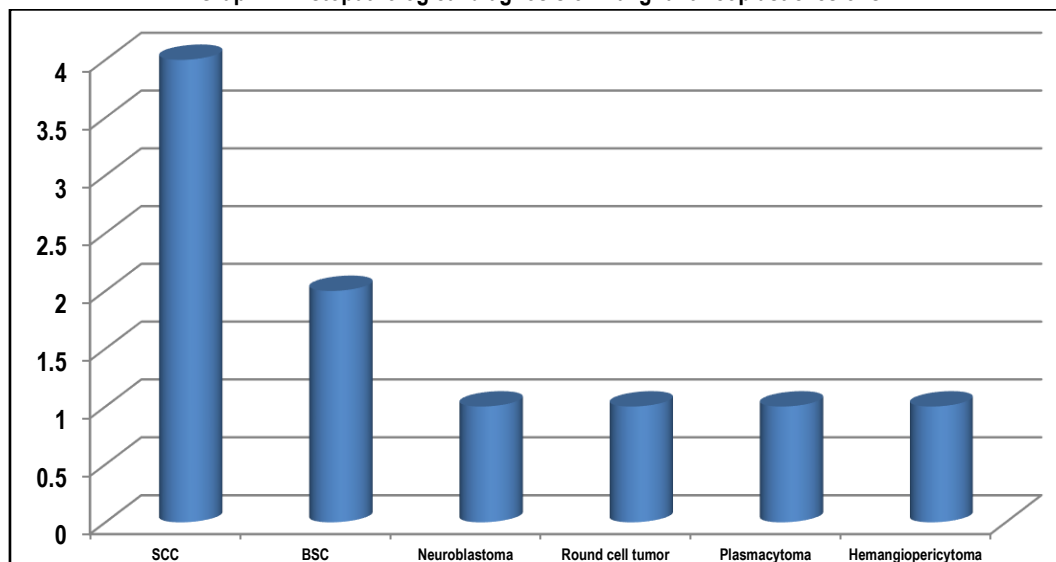
**Table III: Different non- neoplastic and neoplastic lesions**

Non- neoplastic lesions	Number	P value
Fungal infection	10	0.02
Inflammatory polyp	24	
Nasal Glioma	8	
Rhinosporidiosis	6	
<b>Neoplastic lesions</b>		0.01
Benign	18	
Malignant	10	

**Graph I: Histopathological diagnosis of benign neoplastic lesions**



**Graph II: Histopathological diagnosis of malignant neoplastic lesions**



## RESULTS

Table I shows that out of 76 biopsies, 34 were of males and 40 were of females.

Table II shows that out of 76 tissues, non- neoplastic lesions were 48 and neoplastic lesions were 28. The difference was significant ( $P < 0.05$ ).

Table III shows that among non- neoplastic lesions, fungal infection was seen in 10, inflammatory polyp was 24, Nasal Glioma were 8 and Rhinosporidiosis was 6. Neoplastic lesions were benign in 18 cases and malignant in 10.

Graph I show that benign neoplastic lesions were inverted papilloma (8), schwannoma (4), angiofibroma (4) and capillary hemangioma (2). The difference was significant ( $P < 0.05$ ).

Graph II shows that malignant neoplastic lesions were squamous cell carcinoma (4), basal cell carcinoma (2), neuroblastoma (1), round cell tumor (1), plasmacytoma (1) and hemangiopericytoma (1). The difference was significant ( $P < 0.05$ ).

## DISCUSSION

Nose is the organ helps in smell as well as has aesthetic significance. It is most sensitive part of the face. The nasal cavity (or nasal fossa) is a large air-filled space above and behind the nose in the middle of the face. Each cavity is the continuation of one of the two nostrils. Lesions of nasal cavity are quite common.<sup>4</sup> It can be neoplastic and non-neoplastic. Diseases of the nasal cavity include viral, bacterial and fungal infections, nasal cavity tumors as well as inflammations of the nasal mucosa.<sup>5</sup> The present study was conducted to assess lesions of nasal cavity and paranasal sinuses.

In this study, out of 76 biopsies, 34 were of males and 40 were of females. We found that out of 76 tissues, non- neoplastic lesions were 48 and neoplastic lesions were 28. Randy<sup>6</sup> in their study on 162 cases found that maximum neoplastic lesions were squamous cell carcinoma and plasmacytoma was the least in number.

We found that among non- neoplastic lesions, fungal infection was seen in 10, inflammatory polyp was 24, Nasal Glioma was 8 and Rhinosporidiosis was 6. Neoplastic lesions were benign in 18 cases and malignant in 10. Zafar et al<sup>7</sup> found that lesions involving the nasal cavity, paranasal sinuses and nasopharynx are due to many of the specialized issues and the aberrations that exist in the region. Nasal symptoms are one of the most common reasons for which the patients seek medical advice. Upper airways are involved in a variety of non-neoplastic and neoplastic diseases. It is quite impossible to distinguish clinically between such lesions and it is essential that all masses removed from nose and paranasal sinuses should be fully examined histopathologically. The polyps comprised the majority of lesions (70%) followed by malignant lesions (22%).

These lesions are quite common in today's life. Most common causes are allergic, antigenic and obstructive. Early detection and prompt treatment is required to eliminate the lesion. Proper diagnosis on the basis of histopathology is must.<sup>8</sup>

We found that benign neoplastic lesions were inverted papilloma (8), schwannoma (4), angiofibroma (4) and capillary hemangioma (2). Malignant neoplastic lesions were squamous cell carcinoma (4), basal cell carcinoma (2), neuroblastoma (1), round cell tumor (1), plasmacytoma (1) and hemangiopericytoma (1). According to the study by Panchal L<sup>9</sup>, out of 49 cases of carcinoma occurring in nasal cavity and paranasal sinuses 24 (48.97%) were SCC. 105

(10.20%) cases were undifferentiated carcinoma, 3 (6.12%) were TCC and 8 (16.32%) were adenoid cystic carcinoma.

Osborn et al<sup>10</sup> found that out of total 119 cases of polyp, 79 (66.38%) were male subjects and 40 (33.62%) were female subjects with M:F ratio 2:1. Majority of lesions occur in nasal cavity (69%) followed by paranasal sinuses (25%) and nasopharynx (6%). Majority of polyps occur in nasal cavity (75.71%) followed by paranasal sinuses (24.29%). Majority of benign neoplasms occur in the nasal cavity (87.5%) followed by nasopharynx (12.5%). Majority of malignant neoplasms occur in the nasal cavity (40.90%) followed by paranasal sinuses (36.36%) and nasopharynx (22.74%). M Kulkarni A et al studied the incidence of benign and malignant lesions of nose and paranasal sinuses (PNS). The formalin fixed specimens were received with complete clinical and radiological features. Routine gross examination and required number of sections were taken and stained with haematoxylin and eosin. Periodic acid Schiffs and reticulin stains were used wherever necessary. The incidence of lesions in nasal cavity (NC) and PNS was 16.71 cases per year, non-neoplastic lesions constituted 86% of these cases and their incidence was 14.42% and neoplastic lesions constituted 12%. All the cases were carefully examined histopathologically and it was found that the region was affected by variety of lesions. Among 117 cases, 101 were non-neoplastic and 16 were neoplastic. The commonest site was NC, followed by PNS. They occur commonly in second and third decades with predominance in males. Amongst the non-inflammatory lesion, nasal polyp is the commonest lesion followed by rhinoscleroma and rhinosporidiosis. The common age group is second and third decades, with male predominance. Amongst benign neoplastic lesions capillary haemangioma was common followed by inverted papilloma. The common age group is second and third decades, with male predominance. Malignant lesions were comparatively less to that of benign lesions.<sup>11</sup>

Singh SG et al assessed the presentation of Lesions of Nose and Paranasal Sinuses at a Tertiary Care Center in Central India. Among 150 patients there was a male predominance in all lesions except malignant lesions and most of the patients 72 (48%) were in the age group 11- 30 years. Mean age of presentation for benign lesions was 33.64 years and of malignant lesions was 49.14 years. The study showed that 96 (64%) of the nose and PNS lesions were of inflammatory nature followed by 22 (15%) benign, 18 (12%) granulomatous and 14 (9%) malignant, Inflammatory polyp being the most common diagnosis. Haemangioma was the most common benign neoplastic lesion whereas in granulomatous lesions most common diagnosis was tuberculosis. The maximum lesions 74 (49%) were in maxillary antrum. The most common clinical presentation was nasal obstruction, with unilateral nasal obstruction seen in 84 (56%) cases and bilateral nasal obstruction in 50 (33.3%) cases. Angiofibroma 6 (4%) was exclusively seen in adolescent males. Olfactory neuroblastoma 4 (2.6%) was diagnosed in females with mean age of presentation of 30 years. Sinonasal lesions display a complex and interesting spectrum of clinical, radiological and histopathologic features. The non-neoplastic lesions are numerous, the morphologic variants of neoplasms are many and most of them present as polypoid masses which are impossible to distinguish clinically.<sup>12</sup>

## CONCLUSION

It can be concluded that most common lesions were fungal infection, inflammatory polyp, Nasal Glioma and Rhinosporidiosis.

## REFERENCES

1. Zimmer LA, Carrau RL. Neoplasms of the nose and paranasal sinuses. In: Bailey BJ, Johnson JT, Newland SD, editors. *Head & Neck Surgery-Otolaryngology*. 4th ed. Lippincott: Williams & Wilkins; 2006. p. 1482-6
2. Lathi A, Syed MM, Kalakoti P, et al. Clinico-pathological profile of sinonasal masses: a study from a tertiary care hospital of India. *Acta Otorhinolaryngol Ital*. 2011;31:372-77.
3. Rahbor R, Resto UA, Robson CD, et al. Nasal glioma and encephalocele: Diagnosis and management. *Laryngoscope*. 2003;113:2069-77.
4. Humayun AHM, ZahurulHuq AHM, Ahmed SMT, et al. Clinicopathological study of sinonasal masses. *Bangladesh J Otorhinolaryngol*. 2010;16:15-22.
5. Anjali Dasgupta, Ghosh RN, Chhanda Mukherji. Nasal Polyps Histopathological spectrum. *IJO and HNS* 1997; 9 (1): 1-5.
6. Randy Judd, Zaki SR, Lisa M, Coffield BS, Evatt BL. Sinonasal papillomas and Human papilloma virus. *Human Pathology* 1991; 22:550-6.
7. Zafar U, Khan N, Afroz N, Hasa SA. Clinicopathological study of nonneoplastic lesions of nasal cavity and paranasal sinuses. *Indian J Pathol Microbiol* 2008;51:26-9.
8. Hassa al-H, Nidal Hattar. Clinicopathological study of sinonasal lesions at King Hussain Medical center. *JRMS* 2002;9(2):16-8.
9. Panchal L, Vaideeswar P, Kathpal D, Maidwale CV, Prabhat V. Sinonasal Epithelial Tumor: A pathologic study of 69 cases. *J Postgrad Med* 2005;51:30-5.
10. Osborn DA. Nature and behavior of transitional tumors in upper respiratory tract. *Cancer* 1969; 25 (1): 50-60.
11. M Kulkarni A, G Mudholkar V, S Acharya A, V Ramteke R. Histopathological study of lesions of nose and paranasal sinuses. *Indian J Otolaryngol Head Neck Surg*. 2012;64(3):275-9. doi:10.1007/s12070-011-0286-7
12. Singh SG, Qureshi S, Jain L, Jadia S, Sharma S. Presentation of Lesions of Nose and Paranasal Sinuses at a Tertiary Care Center in Central India. *Indian J Otolaryngol Head Neck Surg*. 2018 Jun;70(2):284-9.

**Source of Support:** Nil. **Conflict of Interest:** None Declared.

**Copyright:** © the author(s) and publisher. IJMRP is an official publication of Ibn Sina Academy of Medieval Medicine & Sciences, registered in 2001 under Indian Trusts Act, 1882.

This is an open access article distributed under the terms of the Creative Commons Attribution Non-commercial License, which permits unrestricted non-commercial use, distribution, and reproduction in any medium, provided the original work is properly cited.

**Cite this article as:** Amulya Singh, Neelam Harit. Analysis of Lesions of Nasal Cavity and Para Nasal Sinuses at a Tertiary Care Hospital: A Histopathological Study. *Int J Med Res Prof*. 2019 Mar; 5(2): 293-96. DOI:10.21276/ijmrp.2019.5.2.067