

Evaluation of Microbial Profile of Patients with Post-Traumatic Endophthalmitis: An Institutional based Study

Ravi Kumar¹, Amit Kumar Anand^{2*}

¹Tutor, ²Assistant Professor, Department of Microbiology,
Vardhman Institute of Medical sciences, Pawapuri, Nalanda, Bihar, India.

ABSTRACT

Background: Post-traumatic infectious endophthalmitis is an uncommon but severe complication of ocular trauma. Polymicrobial infections in such cases are very common, but species of Staphylococcus and Bacillus are the commonest reported pathogens.^{7,8} Hence; we planned the present study to assess microbial profile of patients with post-traumatic endophthalmitis.

Materials & Methods: A total of 60 patients with post-traumatic endophthalmitis were included in the present study. On the basis of subjective symptoms and objective signs, a final diagnosis of endophthalmitis was made based. Collection of undiluted vitreous sample was done in by aspiration in a syringe was sent to laboratory for microbiology analysis. Spectrum of microorganisms was obtained and recorded. All the results were analysed by SPSS software.

Results: Visible wound entry was present in 48 patients while in the remaining 12 patients, no visible wound entry was present. Corneal involvement by infection was present in 14 patients while was absent in the remaining 46 patients. S. epidermidis, S. aureus, Streptococcus spp., Bacillus spp.,

Clostridium spp. and Pseudomonas spp. were the common bacteria isolated in the present study.

Conclusion: Microbiological testing of the patients with posttraumatic endophthalmitis should be done so that appropriate treatment could be started.

Key words: Microbiological Profile, Post-Traumatic Endophthalmitis.


*Correspondence to:

Dr. Amit Kumar Anand,
Assistant Professor,
Department of Microbiology, Vardhman Institute of Medical sciences, Pawapuri, Nalanda, Bihar, India.

Article History:

Received: 12-10-2018, Revised: 05-11-2018, Accepted: 29-11-2018

Access this article online

Website: www.ijmrp.com	Quick Response code 
DOI: 10.21276/ijmrp.2018.4.6.051	

INTRODUCTION

Post-traumatic infectious endophthalmitis is an uncommon but severe complication of ocular trauma.^{1,2} The pathogens that cause posttraumatic endophthalmitis are distinct from those in other types of endophthalmitis, and thus it is useful to analyze this condition separately. The course of post-traumatic endophthalmitis is affected by factors including, but not limited to, the type of injury, the microorganisms involved, the presence or absence of an intraocular foreign body (IOFB), and the time between injury and treatment.³⁻⁶ Polymicrobial infections in such cases are very common, but species of Staphylococcus and Bacillus are the commonest reported pathogens.^{7,8} Hence; we planned the present study to assess microbial profile of patients with post-traumatic endophthalmitis.

MATERIALS & METHODS

The present study was conducted in Department of Microbiology, Vardhman Institute of Medical sciences, Pawapuri, Nalanda, Bihar

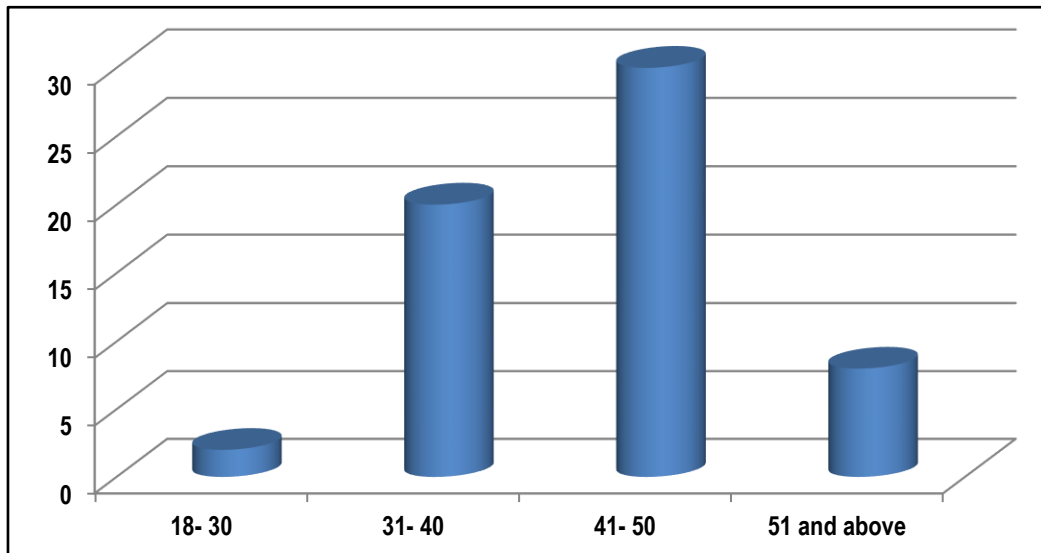
(India) and it included assessment of microbiological profile of patients with post-traumatic endophthalmitis.

Ethical approval was obtained from institutional ethical committee and written consent was obtained after explaining in detail the entire research protocol.

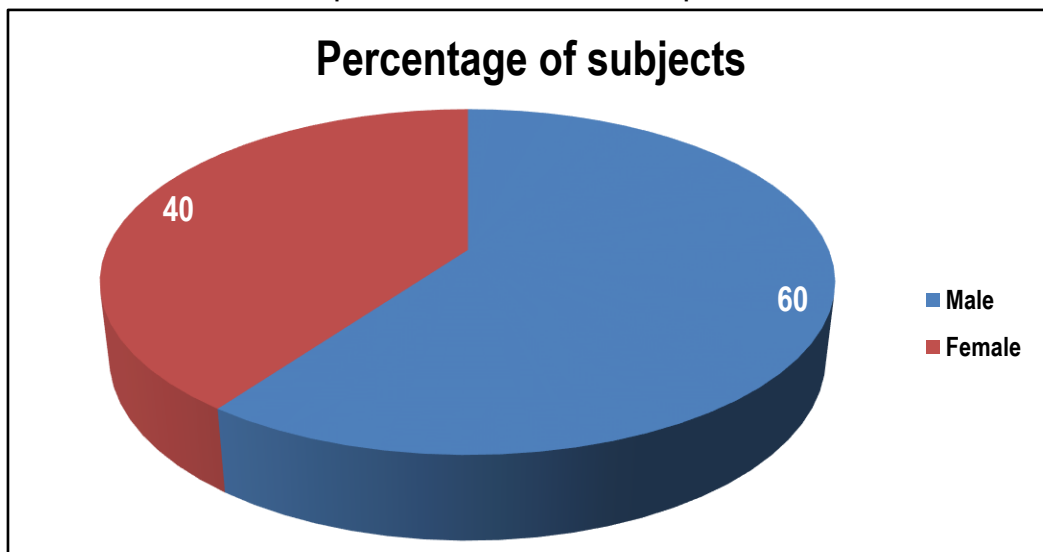
A total of 60 patients with post-traumatic endophthalmitis were included in the present study. A self-framed form was made and all the demographic and clinical details of the all the patients was obtained.

Complete clinical history of all the patients in relation to the ocular area of all the patients was recorded. On the basis of subjective symptoms and objective signs, a final diagnosis of endophthalmitis was made based. Collection of undiluted vitreous sample was done in by aspiration in a syringe was sent to laboratory for microbiology analysis. Spectrum of microorganisms was obtained and recorded. All the results were analysed by SPSS software.

Graph 1: Age-wise distribution of subjects



Graph 2: Gender-wise distribution of patients



Graph 3: Clinical data

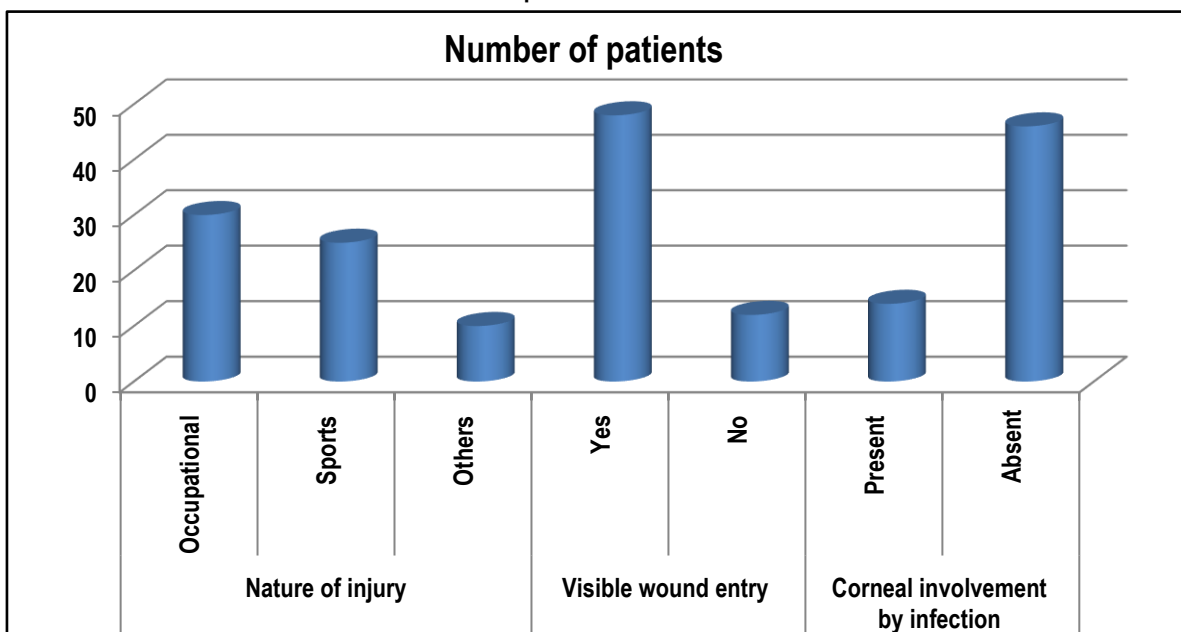


Table 1: Clinical data

Parameter		Number of patients
Nature of injury	Occupational	30
	Sports	25
	Others	10
Visible wound entry	Yes	48
	No	12
Corneal involvement by infection	Present	14
	Absent	46

Table 2: Type of Bacteria Grown in the positive samples

Microorganism		Number of patients
Bacteria	<i>S. epiermidis</i>	6
	<i>S.aureus</i>	1
	<i>Streptococcus spp.</i>	10
	<i>Bacillus spp.</i>	5
	<i>Clostridium spp.</i>	1
	<i>Pseudomonas spp.</i>	8
	Others	2
Fungal		1
Poly-microbial		1

RESULTS

The present study was conducted in the department of microbiology on the 60 patients of post-traumatic endophthalmitis. Mean age of the patients of the present study was 45.8 years. 30 patients belonged to the age group of 41 to 50 years. 20 patients belonged to the age group of 31 to 40 years. 2 patients belonged to the age group of 18 to 30 years. 8 patients belonged to the age group of 51 years and above. 60 percent of the patients of the present study were males while the remaining 40 percent were females. Occupational injury was present in 30 patients, while in 25 patients, sports injury was present. Other types of injury were present in 10 patients. Visible wound entry was present in 48 patients while in the remaining 12 patients, no visible wound entry was present. Corneal involvement by infection was present in 14 patients while was absent in the remaining 46 patients. *S. epiermidis*, *S.aureus*, *Streptococcus spp.*, *Bacillus spp.*, *Clostridium spp.* and *Pseudomonas spp.* were the common bacteria isolated in the present study.

DISCUSSION

Post traumatic endophthalmitis still remains an uncommon but a serious and somewhat devastating complication after repairing of open globe injury. The incidence of post traumatic endophthalmitis varies from 3.3% to 17% in series from large institutions. The likelihood of infection after penetrating trauma surgery is approximately 100 times greater than post elective cataract surgery.^{8,9}

In the present study, mean age of the patients was 45.8 years. 30 patients belonged to the age group of 41 to 50 years. 20 patients belonged to the age group of 31 to 40 years. 2 patients belonged to the age group of 18 to 30 years. 8 patients belonged to the age group of 51 years and above. 60 percent of the patients of the

present study were males while the remaining 40 percent were females. Long C et al investigated the spectrum of pathogens and antibiotic susceptibility of bacterial isolates from a large cohort of post-traumatic endophthalmitis cases. A retrospective study of 912 post-traumatic endophthalmitis patients treated at a tertiary eye-care center in China was performed. The percent susceptibilities for the first 10 years (1990–1999) and the second 10 years (2000–2009) were compared by Chi square test. Three-hundred-forty-seven (38.1%) cases of endophthalmitis were culture-positive, and 11 (3.2%) showed mixed infections (Gram-negative bacilli and fungi), yielding a total of 358 microbial pathogens. Culture proven organisms included 150 (41.9%) Gram-positive cocci, 104 (29.1%) Gram-negative bacilli, 44 (12.3%) Gram-positive bacilli, and 60 (16.8%) fungi. The coagulase-negative staphylococcal (CNS) species *S. epidermidis* (21.8%) and *S. saprophyticus* (12.0%) were the predominant pathogens, followed by *Bacillus subtilis* (8.7%), *Pseudomonas aeruginosa* (7.8%), and *Escherichia coli* (6.4%). Delayed repair over 24 h ($p < 0.001$) and metallic injury ($p < 0.01$) were significantly associated with positive culture of CNS. The most frequent fungal species were *Aspergillus* (26/60), followed by yeast-like fungi (18/60). *P. aeruginosa* was relatively sensitive to ciprofloxacin (83.3%), cefoperazone (75%), tobramycin (75%), cefuroxime (75%), and ceftazidime (75%) during the second decade. Multi-drug resistance was observed in the predominant Gram-negative bacteria. They identified a broad spectrum of microbes causing post-traumatic endophthalmitis, with Gram-positive cocci the most frequently identified causative organism, followed by *Bacillus* species, fungi, and mixed infections.¹⁰

In the present study, occupational injury was present in 30 patients, while in 25 patients, sports injury was present. Other types of injury were present in 10 patients. Visible wound entry

was present in 48 patients while in the remaining 12 patients, no visible wound entry was present. Corneal involvement by infection was present in 14 patients while was absent in the remaining 46 patients. *S. epidermidis*, *S.aureus*, *Streptococcus* spp., *Bacillus* spp., *Clostridium* spp. and *Pseudomonas* spp. were the common bacteria isolated in the present study. Alfaro DV et al evaluated 36 cases of posttraumatic endophthalmitis to determine which factors were associated with visual loss. All cases were treated with intravenous and intraocular antibiotics. Pars plana vitrectomy was performed in 15 (41.7%) cases as an adjunct to treatment. Patients ranged in age from 18 months to 83 years, and included 30 men (83%) and 6 women (17%). Intraocular foreign bodies were present in 6 patients (16.7%), 9 (25%) had corneal lacerations, 13 (36.1%) had corneoscleral or scleral lacerations, and 8 (22.2%) had ocular trauma of unknown type. Of the 36 eyes, 21 (58.3%) had positive culture results, and 10 of these (27.8%) had multiple organisms. The most common isolates were *Staphylococcus* species (26.5%), *Streptococcus* species (20.6%), and *Bacillus* species (14.7%). In 4 cases the diagnosis was made 6 or more years after injury. Final visual acuity was 20/200 in 8 eyes (22.2%) and 20/300 in 1 eye. In 17 cases (47.2%), the eye was salvaged but visual acuity was 5/200 or worse, and 10 eyes (27.8%) were lost to enucleation or phthisis bulbi. Prompt diagnosis and early treatment with intraocular and systemic antibiotics are important in the successful management of posttraumatic endophthalmitis.¹¹

CONCLUSION

Under the light of above obtained results, the authors conclude that microbiological testing of the patients with posttraumatic endophthalmitis should be done so that appropriate treatment could be started. However; further studies are recommended.

REFERENCES

1. Andreoli C. M, Andreoli M. T, Kloek C. E, Ahuero A. E, Vavvas D, Durand M. L. Low rate of endophthalmitis in a large series of open globe injuries. *Am J Ophthalmol.* 2009 Apr;147(4):601–8. e2.
2. Kunimoto DY, Das T, Sharma S, Jalali S, Majji AB, Gopinathan U, Athmanathan S, Rao TN. Microbiologic spectrum and susceptibility of isolates: part II. Posttraumatic endophthalmitis. Endophthalmitis Research Group. *Am J Ophthalmol.* 1999;128(2):242–44.

3. Wykoff CC, Flynn HW Jr, Miller D, Scott IU, Alfonso EC. Exogenous fungal endophthalmitis: microbiology and clinical outcomes. *Ophthalmology.* 2008;115(9):1501–07.
4. Boldt H. C, Pulido J. S, Blodi C. F, Folk J. C, Weingeist T. A. Rural endophthalmitis. *Ophthalmology.* 1989 Dec;96(12):1722–1726.
5. Brinton G. S, Topping T. M, Hyndiuk R. A, Aaberg T. M, Reeser F. H, Abrams G. W. Posttraumatic endophthalmitis. *Arch Ophthalmol.* 1984;102:547–50.
6. Peyman GA, Carroll CP, Raichand M. Prevention and management of traumatic endophthalmitis. *Ophthalmology.* 1980;87(4):320–24.
7. Shrader SK, Band JD, Lauter CB, Murphy P. The clinical spectrum of endophthalmitis: incidence, predisposing factors, and features influencing outcome. *J Infect Dis.* 1990;162(1):115–20.
8. Bhagat N, Nagori S, Zarkin M. Post-traumatic infectious endophthalmitis. *Surv Ophthalmol.* 2011;56(3):214–51.
9. Gharamah A, Moharram A, Ismail M, Al-Hussaini A. Bacterial and fungal endophthalmitis in Upper Egypt: related species and risk factors. *Asian Pacific journal of tropical biomedicine.* 2012;2(8):655–59.
10. Long C, Liu B, Xu C, Jing Y, Yuan Z, Lin X. Causative organisms of post-traumatic endophthalmitis: a 20-year retrospective study. *BMC Ophthalmol.* 2014;14:34.
11. Alfaro DV1, Roth D, Liggett PE. Posttraumatic endophthalmitis. Causative organisms, treatment, and prevention. *Retina.* 1994;14(3):206-11.

Source of Support: Nil. **Conflict of Interest:** None Declared.

Copyright: © the author(s) and publisher. IJMRP is an official publication of Ibn Sina Academy of Medieval Medicine & Sciences, registered in 2001 under Indian Trusts Act, 1882.

This is an open access article distributed under the terms of the Creative Commons Attribution Non-commercial License, which permits unrestricted non-commercial use, distribution, and reproduction in any medium, provided the original work is properly cited.

Cite this article as: Ravi Kumar, Amit Kumar Anand. Evaluation of Microbial Profile of Patients with Post-Traumatic Endophthalmitis: An Institutional based Study. *Int J Med Res Prof.* 2018 Nov; 4(6):237-40. DOI:10.21276/ijmrp.2018.4.6.051