

# Assessment of Efficacy of Transepidermal Administration of Ascorbic Acid Through Microneedling in Melasma: An Institutional Based Study

Raj Kirit E P<sup>1</sup>, Pendyala Pradeep<sup>2\*</sup>

<sup>1</sup>Assistant Professor, Department of Dermatology,  
Malla Reddy Institute of Medical Sciences, Suraram, Hyderabad, Telangana, India.

<sup>2</sup>Assistant Professor, Department of Dermatology,  
Dhanalakshmi Srinivasan Medical College and Hospital, Siruvachur, Perambalur, Tamil Nadu, India.

## ABSTRACT

**Introduction:** Melasma, formerly known as chloasma, is an acquired pigmented condition, occurring most commonly on the face. Hence; the present study was undertaken for assessing the efficacy of transepidermal administration of ascorbic acid through microneedling in Melasma.

**Materials & Methods:** Facial melasma patients were enrolled in the present study. After gentle cleansing with normal saline, topical anesthetic cream was applied over the area to be treated and was left for about 60 min. All the patients received ascorbic acid transepidermally into the melasma lesion using a dermaroller. The Melasma Area and Severity Index (MASI) score was used for assessing the primary outcome, which was as follows: 0: No improvement, 1: Mild response, 2: Moderate response, 3: Good response and 4: Very good response. All the results were recorded in Microsoft excel sheet and were analysed by SPSS software.

**Results:** Grade 2 improvement occurred in 10 percent of the patients while grade 3 improvements occurred in 80 percent of the patients. In the present study, pain at procedural site was

seen in 2 patients while erythema was seen in 1 patient.

**Conclusion:** Transepidermal administration of ascorbic acid through microneedling in Melasma produced excellent results.


**Key words:** Ascorbic Acid, Melasma.

## \*Correspondence to:

**Dr. Pendyala Pradeep,**  
Assistant Professor,  
Department of Dermatology,  
Dhanalakshmi Srinivasan Medical College and Hospital,  
Perambalur, Tamil Nadu, India.

## Article History:

Received: 05-10-2016, Revised: 27-10-2016, Accepted: 18-11-2016

Access this article online	
Website: <a href="http://www.ijmrp.com">www.ijmrp.com</a>	Quick Response code 
DOI: 10.21276/ijmrp.2016.2.6.078	

## INTRODUCTION

Melasma, formerly known as chloasma, is an acquired pigmented condition, occurring most commonly on the face. This disorder, which is more prevalent in females and darker skin types, is predominantly attributed to ultraviolet (UV) exposure and hormonal influences. Melasma is generally a clinical diagnosis consisting of symmetric reticulated hypermelanosis in three predominant facial patterns: centrofacial, malar, and mandibular.<sup>1-3</sup>

Hydroquinone (HQ) and triple combination creams (TCCs) remain the gold standard of treatment. There have been concerns about the side effects and long-term safety of HQ; hence the need to develop alternate treatment options. Current treatment modalities include kojic acid, azelaic acid, arbutin, ascorbic acid, chemical peels and lasers. Newer formulations that are being tried include tranexamic acid (TA), rucinol (4-n-butylresorcinol), oligopeptides silymarin and orchid extracts.<sup>4</sup> Various botanical extracts that have been tried in melasma are grape seed extract,

pycnogenol, aloein, green tea extracts, coffee berry, soy, and licorice extract.<sup>5-7</sup>

Hence; the present study was undertaken for assessing the efficacy of transepidermal administration of ascorbic acid through microneedling in Melasma.

## MATERIALS & METHODS

The present study was conducted for assessment of efficacy of transepidermal administration of ascorbic acid through microneedling in Melasma. Written consent was obtained from all the patients after explaining in detail the entire research protocol. A total of 10 patients of facial melasma were enrolled in the present study.

### Inclusion Criteria

1. Subjects aged 18-50 years with Melasma.
2. Subjects who are willing to sign the written consent form prior to participation in the study.

**Exclusion Criteria**

1. Subjects aged <18 or >50 years.
2. Pregnant and lactating women.
3. Patients taking oral contraceptives.
4. Patients with history of thromboembolism, bleeding disorders, and abnormal coagulogram.

Each patient was subjected to routine blood investigations at the time of reporting along with BT, CT and INR. After gentle cleansing with normal saline, topical anesthetic cream was applied over the area to be treated and was left for about 60 min. All the patients received ascorbic acid transepidermally into the melasma lesion using a dermaroller. The Melasma Area and Severity Index (MASI) score was used for assessing the primary outcome.<sup>8</sup>

**Table 1: Grades of improvement by reduction in MASI Score**

Grades of improvement	Reduction in MASI Score
0. No response	No improvement
1. Mild response	<25% improvement
2. Moderate response	25% to 50% improvement
3. Good response	51% to 75% improvement
4. Very good response	>75% improvement

All the results were recorded in Microsoft excel sheet and were analysed by SPSS software. Chi- square test was used for assessment of level of significance. P- value of less than 0.05 was taken as significant.

**Table 1: Distribution of subjects according to age and gender**

Parameter		Frequency	Percent
Gender	Female	8	80
	Male	2	20
Mean age (years)		32.58	

**Table 2: Distribution of subjects according to various precipitating factors**

Precipitating factor		Frequency	Percentage
Sun light	Present	8	80
	Absent	2	20
Cosmetic system	Present	4	40
	Absent	6	60
Pregnancy	Present	3	30
	Absent	7	70
Family history	Present	1	10
	Absent	9	90

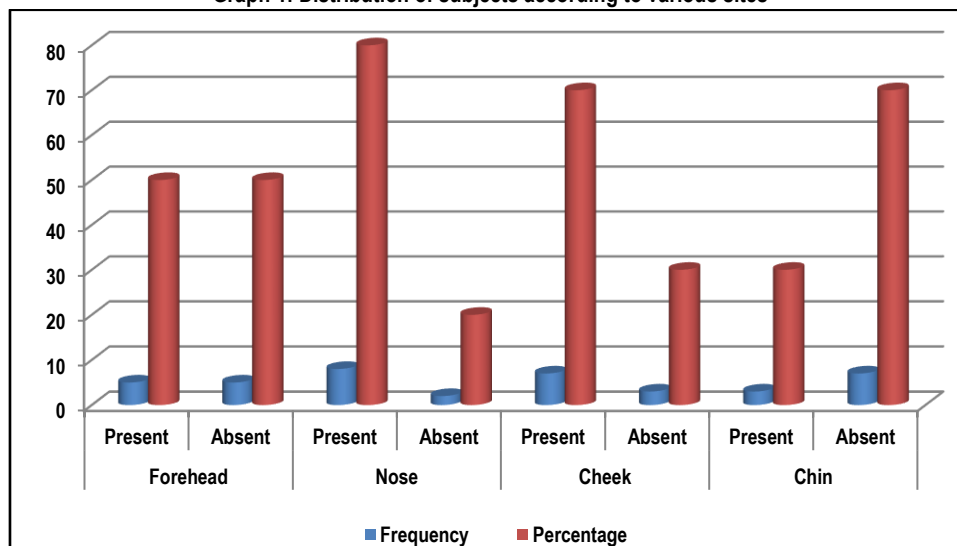
**Table 3: Distribution of subjects of both the study groups according to Grade of improvement**

Grade	Frequency	Percent
2	1	10
3	8	80
4	1	10
Total	10	100

**Table 4: Distribution of subjects according to side-effects**

Grade	Frequency	Percent
Pain at procedural site	2	20
Erythema	1	10

**Graph 1: Distribution of subjects according to various sites**



## RESULTS

In the present study, mean age of the patients was 32.58 years. There were 8 females and 2 males in the present study. Sunlight, cosmetic system, pregnancy and positive family history were found to be precipitating factors in 80 percent, 40 percent, 30 percent and 10 percent of the patients. Forehead involvement occurred in 5 patients, while nose involvement and cheek involvement occurred in 8 patients and 7 patients respectively. Chin involvement occurred in 3 patients. In the present study, grade 2 improvement occurred in 10 percent of the patients while grade 3 improvements occurred in 80 percent of the patients. In the present study, pain at procedural site was seen in 2 patients while erythema was seen in 1 patient.

## DISCUSSION

Melasma (from the Greek word melas, meaning 'black') is a common, acquired, circumscribed hypermelanosis of the sun-exposed skin. It presents as symmetric, hyperpigmented macules having irregular, serrated, and geographic borders. The most common locations are the cheeks, upper lips, the chin, and the forehead, but other sun-exposed areas may also be occasionally involved. Studies indicate the possible role of several risk factors such as genetics, sunlight, age, gender, hormones, pregnancy, thyroid dysfunction, cosmetics, and medications. Melasma is an acquired disorder of skin pigmentation that is more common in people of Oriental, Hispanic, and Indo-Chinese origin and affects females much more commonly than males. Melasma often causes a significant psychological impact with a negative effect on quality of life and emotional well-being.<sup>7-9</sup> Hence; the present study was undertaken for assessing the efficacy of transepidermal administration of ascorbic acid through microneedling in Melasma. In the present study, mean age of the patients was 32.58 years. There were 8 females and 2 males in the present study. Sunlight, cosmetic system, pregnancy and positive family history were found to be precipitating factors in 80 percent, 40 percent, 30 percent and 10 percent of the patients. Espinal-Perez LE assessed sixteen women with idiopathic melasma. After randomization by another clinician, they were instructed to use, at night, 5% ascorbic acid cream on one side of the face and 4% hydroquinone cream on the other side, for 16 weeks. Sunscreen was applied daily throughout the period of observation. They were evaluated every month by colorimetry, digital photography, and regular color slides. Subjective evaluation by each patient was also taken into account. The best subjective improvement was observed on the hydroquinone side with 93% good and excellent results, compared with 62.5% on the ascorbic acid side ( $P < 0.05$ ); however, colorimetric measures showed no statistical differences. Side-effects were present in 68.7% (11/16) with hydroquinone vs. 6.2% (1/16) with ascorbic acid. Although hydroquinone showed a better response, ascorbic acid may play a role in the therapy of melasma as it is almost devoid of side-effects; it could be used alone or in combination therapy.<sup>10</sup>

In present study, forehead involvement occurred in 5 patients, while nose involvement and cheek involvement occurred in 8 patients and 7 patients respectively. Chin involvement occurred in 3 patients. In the present study, grade 2 improvement occurred in 10 percent of the patients while grade 3 improvements occurred in 80 percent of the patients. Huh CH et al evaluated the efficacy of vitamin C iontophoresis for melasma patients. Twenty-nine

females with melasma were enrolled. For iontophoresis, a vitamin C solution was applied to one side of the face, while distilled water was applied to the other side as a control. The L (luminance) value was measured by a colorimeter to obtain an objective pigmentation parameter. Twelve weeks after iontophoresis, the colorimeter of the treated site showed a significant decrease in the L value (from 4.60 to 2.78,  $p = 0.002$ ), compared to that of the control site (from 4.45 to 3.87,  $p = 0.142$ ). Vitamin C iontophoresis may be an effective treatment modality for melasma.<sup>11</sup>

In the present study, pain at procedural site was seen in 2 patients while erythema was seen in 1 patient. Guevara IL et al assessed the safety and efficacy of a cream containing 4% hydroquinone, 10% buffered glycolic acid, vitamins C and E, and sunscreen vs. a cream containing sunscreen alone in the depigmentation of epidermal melasma of the face. Thirty-nine Hispanic women, Fitzpatrick skin types III-V, with bilateral epidermal melasma was enrolled in a randomized controlled trial lasting 12 weeks. Patients underwent twice-daily full-face application with the study cream or with the cream containing sunscreen only. Changes in pigmentation were measured using a mexameter, the melasma area and severity index (MASI), and a global evaluation by the patient and blind investigator. Safety evaluations were performed at each follow-up visit. Thirty-five patients completed the trial. Irritation was more common with the study cream but resolved with temporary cessation of cream application and the addition of moisturizers. Mexameter results demonstrated a significant decrease in the degree of pigmentation using the study cream compared with the cream containing sunscreen alone ( $P < 0.0001$ ). Fifteen of 20 patients (75%) using the study cream improved, whereas only two of 15 patients (13%) improved using sunscreen alone. A cream containing 4% hydroquinone, 10% buffered glycolic acid, vitamins C and E, and sunscreen is safe and effective in the treatment of melasma.<sup>12</sup>

## CONCLUSION

From the above results, it can be concluded that transepidermal administration of ascorbic acid through microneedling in Melasma produced excellent results.

## REFERENCES

1. Pichardo R, Vallejos Q, Feldman SR, Schulz MR, Verma A, Quandt SA, et al. The prevalence of melasma and its association with quality of life in adult male Latino migrant workers. *Int J Dermatol.* 2009;48(1):22–26.
2. Hilete M. Skin diseases seen in Kazanchis health center. *Ethiop Med J.* 1998;36(4):245–54.
3. Vazquez M, Maldonado H, Benmaman C, Sanchez JL. Melasma in men. A clinical and histologic study. *Int J Dermatol.* 1988;27(1):25–7.
4. Jo HY, Kim CK, Suh IB, Ryu SW, Ha KS, Kwon YG, et al. Co-localization of inducible nitric oxide synthase and phosphorylated Akt in the lesional skins of patients with melasma. *J Dermatol.* 2009;36(1):10–6.
5. Seckin HY, Kalkan G, Bas Y, Akbas A, Onder Y, Ozyurt H, et al. Oxidative stress status in patients with melasma. *Cutan Ocular Toxicol.* 2014;33(3):212–7.
6. Sarkar R, Puri P, Jain RK, Singh A, Desai A. Melasma in men: a clinical, aetiological and histological study. *J Eur Acad Dermatol Venereol.* 2010;24(7):768–72.

7. El-Essawi D, Musial JL, Hammad A, Lim HW. A survey of skin disease and skin-related issues in Arab Americans. *J Am Acad Dermatol.* 2007;56(6):933–8.
8. Majid I, Haq I, Imran S, Keen A, Aziz K, Arif T. Proposing melasma severity index: A new, more practical, office-based scoring system for assessing the severity of melasma. *Indian J Dermatol.* 2016 Jan-Feb;61(1):39-44.
9. Tamega Ade A, Miot HA, Moco NP, Silva MG, Marques ME, Miot LD. Gene and protein expression of oestrogen-beta and progesterone receptors in facial melasma and adjacent healthy skin in women. *Int J Cosmet Sci.* 2015;37(2):222–8.
10. Espinal-Perez LE, Moncada B, Castanedo-Cazares JP. A double-blind randomized trial of 5% ascorbic acid vs. 4% hydroquinone in melasma. *Int J Dermatol.* 2004 Aug;43(8):604-7.
11. Huh CH, Seo KI, Park JY, Lim JG, Eun HC, Park KC. A randomized, double-blind, placebo-controlled trial of vitamin C iontophoresis in melasma. *Dermatology.* 2003;206(4):316-20.
12. Guevara IL, Pandya AG. Safety and efficacy of 4% hydroquinone combined with 10% glycolic acid, antioxidants, and sunscreen in the treatment of melasma. *Int J Dermatol.* 2003 Dec;42(12):966-72.

**Source of Support:** Nil.

**Conflict of Interest:** None Declared.

**Copyright:** © the author(s) and publisher. IJMRP is an official publication of Ibn Sina Academy of Medieval Medicine & Sciences, registered in 2001 under Indian Trusts Act, 1882. This is an open access article distributed under the terms of the Creative Commons Attribution Non-commercial License, which permits unrestricted non-commercial use, distribution, and reproduction in any medium, provided the original work is properly cited.

**Cite this article as:** Raj Kirit E P, Pendyala Pradeep. Assessment of Efficacy of Transepidermal Administration of Ascorbic Acid Through Microneedling in Melasma: An Institutional Based Study. *Int J Med Res Prof.* 2016; 2(6): 352-55.  
DOI: 10.21276/ijmrp.2016.2.6.078