

Analysis of Efficacy of Mycobacterium W Vaccine in Treating Cutaneous Warts: An Observational Study

Pendyala Pradeep¹, Raj Kirit E P²*

¹Assistant Professor, Department of Dermatology, Dhanalakshmi Srinivasan Medical College and Hospital, Siruvachur, Perambalur, Tamil Nadu, India.

²Assistant Professor, Department of Dermatology, Malla Reddy Institute of Medical Sciences, Suraram, Hyderabad, Telangana, India.

ABSTRACT

Introduction: Warts are a common malady that affects people of all ages, male or female. Warts are the cutaneous manifestations of human papilloma virus (HPV) infection. Hence; the present study was undertaken for assessing the efficacy of mycobacterium W vaccine in treating cutaneous warts.

Materials & Methods: A total of 30 patients of cutaneous warts were enrolled in the present study. All the patients received 0.1 ml of intralesional injection of Mycobacterium W vaccine using an insulin syringe at the base of single cutaneous wart. Intralesional injection was repeated at intervals of three weeks, till there is complete clearance of all warts or maximum of 3 injections. In case of multiple warts, intralesional injection was given in largest wart and the injections were repeated at the same site.

Results: Complete response was found to be present in 29 patients while only single patient exhibited incomplete response. Significant results were obtained while assessing the effect of intralesional Mycobacterium W on warts. Abscess,

inflammation and pain were the common complications encountered.

Conclusion: Mycobacterium W vaccine is a safe and effective line of treatment in treating patients with cutaneous warts.


Key words: Cutaneous, Mycobacterium, Warts.

*Correspondence to:

Dr. Raj Kirit E P,
Assistant Professor,
Department of Dermatology,
Malla Reddy Institute of Medical Sciences,
Suraram, Hyderabad, Telangana, India..

Article History:

Received: 19-08-2016, **Revised:** 06-09-2016, **Accepted:** 27-09-2016

Access this article online	
Website: www.ijmrp.com	Quick Response code 
DOI: 10.21276/ijmrp.2016.2.5.064	

INTRODUCTION

Warts are a common malady that affects people of all ages, male or female. Warts are the cutaneous manifestations of human papilloma virus (HPV) infection. HPV is a double-stranded deoxyribonucleic acid (DNA), non-enveloped virus that belongs to the Papovaviridae family and Papillomavirus genus. They show tropism for epithelial cells, hence causing muco-cutaneous manifestations. The exact mechanism of action of the Mycobacterium w vaccine (MWV) in the clearance of warts is not known.¹⁻³ The exact mechanism of action of the Mycobacterium w vaccine (MWV) in the clearance of warts is not known. The intralesional MWV initiates a strong proinflammatory delayed-type of hypersensitivity response against Mycobacterium w (Mw), which attracts the antigen-presenting cells, leads to the production of helper T-cell type I cytokines and causes activation of the natural killer and cytotoxic T cells. These antigen processing cells may recognise and process the HPV particles in the infected tissue.^{4,5}

The intralesional MWV initiates a strong proinflammatory delayed-type of hypersensitivity response against Mycobacterium w (Mw), which attracts the antigen-presenting cells, leads to the production of helper T-cell type I cytokines and causes activation of the natural killer and cytotoxic T cells. These antigen processing cells may recognise and process the HPV particles in the infected tissue.^{6,7}

Hence; the present study was undertaken for assessing the efficacy of mycobacterium W vaccine in treating cutaneous warts.

MATERIALS & METHODS

The present study was conducted for assessment of efficacy of intralesional mycobacterium W vaccine in treating cutaneous wart patients. Written informed consent was obtained from all the patients after explaining in detail the entire research protocol. A total of 30 patients of cutaneous warts were enrolled in the present study. All the patients received 0.1 ml of intralesional

injection of Mycobacterium W vaccine using an insulin syringe at the base of single cutaneous wart. Intralesional injection was repeated at intervals of three weeks, till there is complete clearance of all warts or maximum of 3 injections. In case of multiple warts, intralesional injection was given in largest wart and the injections were repeated at the same site. Follow-up was done and associated complications were recorded. All the results were summarized in Microsoft excel sheet and were analyzed by SPSS software. Chi- square test was used for assessment of level of significance.

RESULTS

In the present study, a total of 30 patients with presence of cutaneous warts were enrolled. Mean age of the patients of the

present study was 43.8 years. Out of 30 patients, 18 patients belonged to the age group of 30 to 50 years. Among these 30 patients, 19 patients were males while the remaining were females. Foot involvement alone occurred in 50 percent of the patients while hand involvement alone occurred in 20 percent of the patients.

In the present study, complete response was found to be present in 29 patients while only single patient exhibited incomplete response. Significant results were obtained while assessing the effect of intralesional Mycobacterium W on warts.

In the present study, abscess, inflammation and pain were the common complications encountered. Abscess was found to be present in 2 patients, while inflammation was found to be present in 10 patients. Pain was also found to be present in 2 patients.

Table 1: Clinical involvement

Clinical involvement	Number of patients	Percentage of patients
Hand	6	20
Foot	15	50
Both	3	10
Others	6	20

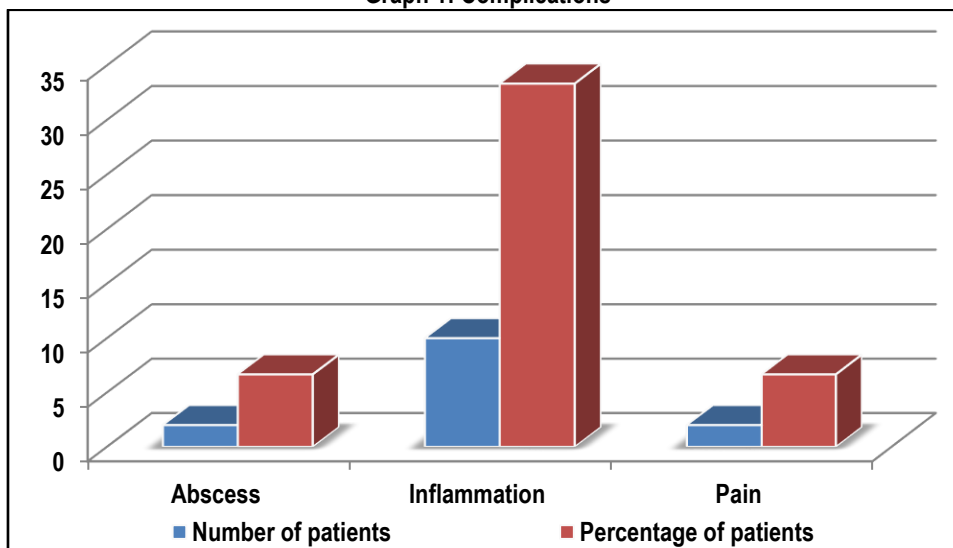
Table 2: Effect on wart

Effect on wart	Number of patients	Percentage of patients	p- value
Complete response	29	96.67	0.000
Incomplete response	1	3.33	
Total	30	100	

Table 3: Complications

Complications	Number of patients	Percentage of patients
Abscess	2	6.67
Inflammation	10	33.33
Pain	2	6.67

Graph 1: Complications



DISCUSSION

Mycobacterium indicus pranii or Mycobacterium W is rapid growing nontubercular mycobacteria, which has been found to induce a strong proinflammatory response while injected intralesionally. There is a prominent delayed hypersensitivity response with an increase in T helper 1 cytokines such as IL2, IL4,

IL6, and IFN gamma and activation of natural killer cells and cytotoxic T cells. The HPV laden cells are caught in the crossfire leading to clearance of warts both at the site of injection and distally.^{8,9} Hence; the present study was undertaken for assessing the efficacy of mycobacterium W vaccine in treating cutaneous warts.

In the present study, a total of 30 patients with presence of cutaneous warts were enrolled. Mean age of the patients of the present study was 43.8 years. Out of 30 patients, 18 patients belonged to the age group of 30 to 50 years. Among these 30 patients, 19 patients were males while the remaining were females. Foot involvement alone occurred in 50 percent of the patients while hand involvement alone occurred in 20 percent of the patients. Singh S et al evaluated the efficacy and safety profile of intralesional injected killed Mw vaccine for the treatment of extensive extragenital cutaneous warts. In this study, a retrospective analysis of medical records was performed in patients with cutaneous warts treated with intralesional Mw vaccine. Only patients with more than 5 extra-genital warts, involving at least two body sites and which had not shown any signs of spontaneous regression over 6 months were treated with the vaccine. Forty four patients were treated with intralesional Mw vaccine. The mean number of warts was 41.5 ± 25.7 with disease duration of 3.1 ± 2.5 years. Complete clearance was achieved in 24 (54.5%) patients with a mean of 3.4 ± 1.1 intralesional injections. Cosmetically acceptable response to therapy (>75% clearance) was achieved in 37 (84.1%) patients. Wart response at distant sites was seen in 38 (86.3%) patients. Thirty-six patients (81.8%) experienced mild therapy-related side effects. Eighteen patients with complete response were followed up for 5.27 ± 1.7 months and none had recurrence of lesions. Killed Mw vaccine is safe and effective in the treatment of extensive cutaneous warts.^{9,10}

In the present study, complete response was found to be present in 29 patients while only single patient exhibited incomplete response. Significant results were obtained while assessing the effect of intralesional Mycobacterium W on warts. Garg S et al conducted a study to assess the efficacy and safety of intralesional Mycobacterium w vaccine for the treatment of warts at sites that were difficult to treat. Thirty patients with at least one wart present on either the plantar surface of their feet, palms, volar aspect of their fingers, or periungual or subungual region, were treated with 0.1 ml of killed Mycobacterium w vaccine given intralesionally in a single wart, without any prior sensitisation dose. Thereafter, a single injection of 0.1 ml of vaccine was given at intervals of four weeks in a single wart till there was complete resolution of the warts or a maximum of 10 injections. Treatment was stopped if there was no response after three injections. The patients were followed up for at least six months. Out of the 30 patients, 28 (93.33%) patients had complete resolution of their warts, both at the injected and distant sites. The mean (SD) time for complete clearance of warts was $43.71(32.82)$ days and the mean (SD) dose of vaccine that was required for complete clearance of warts was 0.186 ml (0.101). Four patients (14.28%) had a recurrence of warts. The treatment was well-tolerated and the side effects were reversible in the majority of the patients. No sensitisation dose was given, only a single wart was injected at a time and the duration between the period of injections was increased to four weeks.¹¹ In the present study, abscess, inflammation and pain were the common complications encountered. Abscess was found to be present in 2 patients, while inflammation was found to be present in 10 patients. Pain was also found to be present in 2 patients.

CONCLUSION

From the above results, the authors concluded that mycobacterium W vaccine is a safe and effective line of treatment in treating patients with cutaneous warts.

REFERENCES

1. Antonsson A, Forslund O, Ekberg H, et al. The ubiquity and impressive genomic diversity of human skin papillomaviruses suggest a commensalic nature of these viruses. *J Virol*. 2000;74(24):11636–41.
2. de Villiers EM, Fauquet C, Broker TR, et al. Classification of papillomaviruses. *Virology*. 2004;324(1):17–27.
3. Meena JK, Malhotra AK, Mathur DK, Mathur DC. Intralesional immunotherapy with Mycobacterium w vaccine in patients with multiple cutaneous warts: Uncontrolled open study. *JAMA Dermatol*. 2013;149:237–9.
4. Dall'oglio F, D'Amico V, Nasca MR, Micali G. Treatment of cutaneous warts: an evidence-based review. *Am J Clin Dermatol*. 2012;13(2):73–96.
5. Kumar P, Dar L, Saldiwal S, Varma S, Datt Upadhyay A, Talwar D, et al. Intralesional injection of mycobacterium w vaccine vs imiquimod, 5%, cream in patients with anogenital warts: A randomized clinical trial. *JAMA Dermatol*. 2014;150:1072–8.
6. Wiltz OH, Torregrosa M, Wiltz O. Autogenous vaccine: The best therapy for perianal condyloma acuminata? *Dis Colon Rectum*. 1995;38:838–41.
7. Chandrashekar L. Intralesional immunotherapy for the management of warts. *Indian J Dermatol Venereol Leprol*. 2011;77:261–3.
8. Berman A, Winkelmann RK. Involuting common warts. *J Am Acad Dermatol*. 1980;3(4):356–62.
9. Bacelieri R, Johnson SM. Cutaneous warts: an evidence-based approach to therapy. *Am Fam Physician*. 2005;72(4):647–52.
10. Singh S, Chouhan K, Gupta S1. Intralesional immunotherapy with killed Mycobacterium indicus pranii vaccine for the treatment of extensive cutaneous warts. *Indian J Dermatol Venereol Leprol*. 2014 Nov-Dec;80(6):509-14.
11. Garg S, Baveja S. Intralesional immunotherapy for difficult to treat warts with Mycobacterium w vaccine. *J Cutan Aesthet Surg*. 2014;7(4):203–8.

Source of Support: Nil. **Conflict of Interest:** None Declared.

Copyright: © the author(s) and publisher. IJMRP is an official publication of Ibn Sina Academy of Medieval Medicine & Sciences, registered in 2001 under Indian Trusts Act, 1882.

This is an open access article distributed under the terms of the Creative Commons Attribution Non-commercial License, which permits unrestricted non-commercial use, distribution, and reproduction in any medium, provided the original work is properly cited.

Cite this article as: Pendyala Pradeep, Raj Kirit E P. Analysis of Efficacy of Mycobacterium W Vaccine in Treating Cutaneous Warts: An Observational Study. *Int J Med Res Prof*. 2016; 2(5): 284-86.