

## Two Case Reports of Rare Fasciolopsis Buski Infestation

Sarkar K<sup>1</sup>, Gonjhu D<sup>1</sup>, Pramanik N<sup>2</sup>

<sup>1</sup>Assistant Professor, <sup>2</sup>Associate Professor, Tropical Medicine,  
School of Tropical Medicine, Kolkata, INDIA.

### Article History

Received: 24 Jan 2016

Revised: 26 Jan 2016

Accepted: 29 Jan 2016

### \*Correspondence to:

Kumkum Sarkar  
School of Tropical  
Medicine, Kolkata  
108, C R Avenue  
Kolkata, India  
dr.kumkum.sarkar@gmail.com

### ABSTRACT

*Fasciolopsis buski* (*F. buski*) is the largest intestinal fluke. Fasciolopsiasis is a disease caused by this fluke, which is endemic in the Far East and Southeast Asia. We are reporting two unusual cases, in which a 34 year women presented with diarrhea, whose stool sample examination revealed the presence of eggs of *F. buski* and another patient 13-year-old girl vomited out 3 live adult worms. The worms were identified as *F. buski* based on gross morphology. Both the patients were successfully treated with Praziquantel. Finding of eggs of *F. buski* in stool examination and presence of live adult worms in the vomitus of a child in a non-endemic area is extremely rare and raises the possibility of unidentified cases in that region.

**KEYWORDS:** Endemic, Intestinal trematode, Plant-borne, Praziquantel.

### INTRODUCTION

*Fasciolopsis buski*, a duodenal digenetic trematode, of the Fasciolidae family, was described for the first time by Busk in the duodenum of a sailor in 1843 in London and its life cycle in humans was first described by Barlow in 1925<sup>1</sup>. The adult worm is found in the duodenum and jejunum of pig and man, where they lay unembryonated eggs, which are excreted out in the faces and undergo further development in water. A ciliated miracidium develops inside the egg and comes out to penetrate a suitable snail host. Asexual multiplication takes place inside the snail to form a large number of cercariae which emerge from the snail and encyst to metacercariae on the surface of aquatic plants<sup>2</sup>. Human get infected by eating contaminated raw water plants, especially when peeling off the outer layers with their teeth. It explains the high prevalence of this disease among children and people living near water chestnut and water caltrop plantations<sup>3</sup>. After infection most human remains asymptomatic. The clinical signs and symptoms of severe infection are abdominal pain, vomiting, diarrhea, low-grade fever, and generalized edema may be seen. Diagnosis is made by detecting eggs in stool or detecting adult worm in stool or vomitus<sup>2</sup>. The worm cause damage to human body by three ways-mechanical, obstructive and toxic. At the site of attachment in mucosal layer they produces ulcer. A large number of worms may hamper digestion and can cause obstruction. Toxic metabolites cause edema of face, abdomen and lower extremities. There may be leukocytosis with eosinophilia upto 35% but leucopenia with lymphocytosis can also be seen<sup>4</sup>.

### CASE REPORT

#### Case 1:

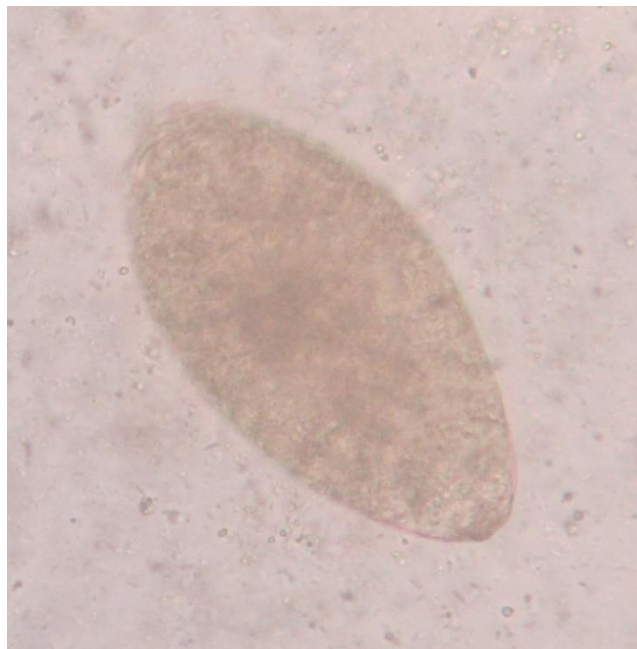
A 39-year-old female presented with intermittent diarrhea with occasional pain abdomen for about 2 months and generalized weakness for 15 days. She had associated loss of appetite and 2 kg weight loss during this 2 month. On examination, she had pallor and glossitis but systemic examination was normal. Laboratory investigations revealed hemoglobin of 7.29 g/dl and peripheral blood film showed microcytic, hypochromic red blood cells. Stool examination was positive for the eggs of *Fasciolopsis buski* (Fig 1). The egg measured 140 x 72.5 µm and was operculated. A distinction between eggs of *Fasciolopsis buski* and *Fasciola hepatica* is difficult to make. Since this patient is from India and had no history of traveling overseas or to any areas endemic for *F. hepatica*, we identified the egg as being that of *F. buski*. She was diagnosed as a case of fasciolopsiasis and was successfully treated with praziquantel and iron supplementation.

#### Case 2:

A 13-year-old girl vomited out 3 live fleshy worms in the morning during playing. Her parents took the expelled worms in to a container, which were referred to the department of Tropical medicine for further treatment. They had given history of occasional abdominal discomfort, nausea, and mild distension of abdomen prior to this. The patient had no history of travel but had history of consumption of water chestnuts. Her physical examination was normal but she was underweight for her age and height. Then we transferred

the worms to a petridish and send it to the department of Helminthology for examination. The worms were leaf-shaped, dorsoventrally flattened, non-segmented, and reddish brown in colour. It had both oral and ventral suckers and cephalic cone was absent (Fig 2) which resembled *Fasciolopsis buski*.

Her stool examination revealed the presence of bile stained, operculated eggs about 135 x 80 µm in size resembling ova of a fluke. Routine laboratory investigations revealed Hb 10.2 gm%, TLC 8400/cu mm, Differential count: P-69, L 21, E 10, and ESR 34 mm/hr. She was diagnosed as a case of fasciolopsiasis



**Fig 1: Ova of *Fasciolopsis buski* on stool examination.**

For this reason, high degree of suspicion is required for diagnosis in a non-endemic area like ours and diagnosis is made by identifying egg stage in stool as adult worms are very rarely seen, except in autopsy<sup>2</sup>. Bunnag *et al* (1983) recommended a single dose of praziquantel (15 mg/kg) of body weight for the treatment of fasciolopsiasis and we had also successfully treated both the patient with praziquantel. Fasciolopsiasis is a food-borne parasitic zoonosis which infects farm pigs and remains a public health problem. It is most prevalent in school-age children<sup>3</sup>. Hence, all children with gastrointestinal symptoms should be screened for parasites before being prescribed deworming<sup>2</sup>.

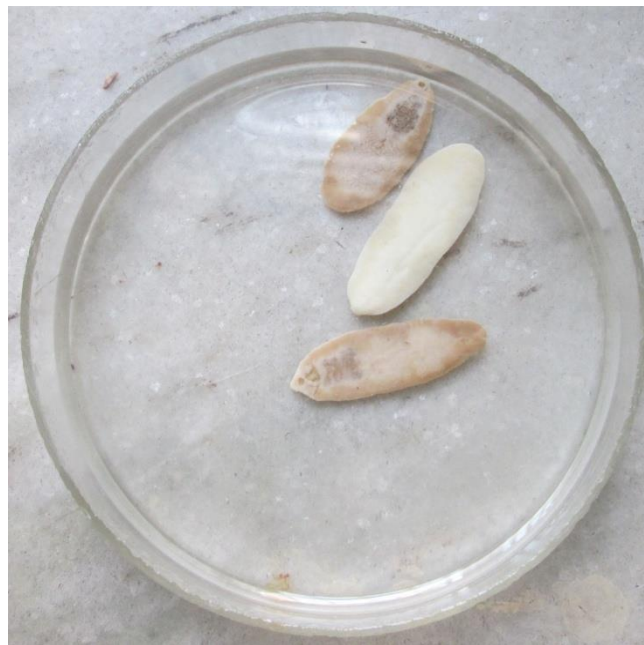## REFERENCES

1. Mahajanet al. - Fasciolopsisbuski in an ileostomy opening: J Infect DevCtries2010; 4(6):401-403.
2. Indrani Mohanty, M V Narasimham, Susmita Sahu, Pritilata Panda, Banojini Parida. Live Fasciolopsisbuski vomited out by a boy: Annals of Tropical Medicine and Public Health 2012 ;5:4;403-405.
3. M Rohela , I Jamaiah, J Menon and J Rachel.

and was successfully treated with praziquantel and iron supplementation.

## DISCUSSION

Reports of *F. buski* infestation in India have been mainly done from Bihar, Uttar Pradesh, and Maharashtra and sporadically from other states like Assam and West Bengal<sup>5</sup>. Fasciolopsiasis seem to be restricted to areas where water vegetations such as water chestnut, water caltrops, water bamboo are eaten abundantly especially if consumed uncooked. Most cases of Fasciolopsiasis are asymptomatic.



**Fig 2: Adult worm of *Fasciolopsis buski* recovered from the vomiting.**

Fasciolopsiasis: a first case report from Malaysia: Southeast Asian J Trop Med Public Health, Vol 36 No. 2 March 2005.

4. MD. Hafeez. Helminth Parasites of Public Health Importance – Trematodes: Journal of Parasitic Diseases, Vol. 27 (2) Dec. 2003, pp. 69-75.

5. Abhisek Mitra, Palash Das, Siddhartha Bhowmik et al., 2015. “Fasciolopsisbuski in a 15 years old girl in Kolkata: A case report”, International Journal of Current Research, 7, (5), 16135-16136.

**Copyright:** © the author(s) and publisher IJM RP. This is an open access article distributed under the terms of the Creative Commons Attribution Non-commercial License, which permits unrestricted non-commercial use, distribution, and reproduction in any medium, provided the original work is properly cited.

**Cite this article as:** Sarkar K, Gonjhu D, Pramanik N. Two Case Reports of Rare Fasciolopsis Buski Infestation. Int J Med Res Prof. 2016, 2(1); 80-81.