

## Retrospective Evaluation of Complications Occurring in Patients Undergoing Proximal Femoral Nail Fixation

Indranil Dutt

Associate Professor, Department of Orthopaedics,  
Mata Gujri Memorial Medical College & Lions Seva Kendra Hospital, Kishanganj, Bihar, India.

### Article History

Received: 17 Aug 2015

Revised: 09 Sept 2015

Accepted: 26 Sept 2015

### \*Correspondence to:

Dr. Indranil Dutt,  
Associate Professor,  
Department of  
Orthopaedics, Mata  
Gujri Memorial  
Medical College,  
Kishanganj, Bihar.

### ABSTRACT

**Background:** The current approach for fractures involving the intertrochanteric region is to initially perform an anatomical reduction and then stabilize the fracture with rigid fixation. This study evaluates the clinical results, radiographic findings, and associated complications in patients who underwent osteosynthesis with PFN for fracture of the proximal femur.

**Material & Methods:** The present study done on 152 patients (152 hips) who were followed up for at least 6 months were included in the study. According to the AO/OTA classification criteria, A1, A2, and A3 type fractures were found in 22 (14.47%), 109 (71.71%), and 21 (13.8%) patients, respectively. The relationship between the complications and SWS score, age, sex, fracture type, reduction quality, and time from fracture to surgery was evaluated.

**Results:** Our study showed that the, 90 (59.21%) were females and 62 (40.78%) were males. The mean age was 74 (range 21–93) years, and the mean follow-up duration was 23.2 (range 7–49) months. 72 patients (47.36%) had left hip fractures, and 80 (52.63%) had right hip fractures. The SWS scores were excellent, good, moderate, and poor in 91 (59.8%), 45 (29.6%), 15 (9.8%), and one (0.6%) patients, respectively. Late postoperative complications were seen in 27 patients (17.7%).

**Conclusion:** We concluded that the quality of fracture reduction is an important factor that affects the revision rate and SWS score in patients with mechanical complications after PFN was used for proximal fractures of femur.

**KEYWORDS:** Proximal End Of Femur, Inter Nailing Fixation, Complications, SWS Score.

### INTRODUCTION

Fractures of tibia shaft are itself a great dilemma and become more difficult to treat when it becomes a compound fracture. High energy trauma has resulted in complex or comminuted fractures, which are frequently open with significant loss of skin and soft tissues and may be associated with compartment syndrome or neuro-vascular injury. Such fractures, when associated with vascular injuries, historically had a very poor outcome.

The Gustilo classification has been the most widely used system and is generally accepted as the primary classification system for open fractures. This system takes into consideration the energy of the fracture, soft-tissue damage, and the degree of contamination.<sup>1</sup> In order to improve fracture healing, more “biological”

methods have been developed over the last decades trying to lessen the surgical dissection, preserving the blood supply to the bony fragments and containing at least partially the fracture haematoma.<sup>2</sup>

Restoration of length, axial alignment, and rotation is essential, but anatomical reduction of every fracture fragment is not very essential.<sup>3</sup>

Fractures involving the trochanteric area of the proximal femur are classified according to the American Orthopedic/Orthopedic Trauma Association (AO/OTA) classification system as AO/OTA 31-A, which delineates them as extracapsular fractures of the hip. These fractures are then subdivided into groups A1, A2, and A3. Simple, two-part fractures are classified as A1 fractures, whereas A2 fractures have multiple fragments.

More complex fractures, including reverse oblique and transverse fracture patterns, are classified as A3.<sup>4</sup> The current approach for fractures involving the intertrochanteric region is to initially perform an anatomical reduction and then stabilize the fracture with rigid fixation.<sup>5</sup>

Cephalomedullary nails, such as the gamma nail and proximal femoral nail (PFN), are the preferred implants in proximal extracapsular femoral fractures (AO/OTA 31-A).<sup>6,7</sup>

Compared with other implants, cephalomedullary nails provide biomechanical advantages because of their shorter lever arms and decreased deformity forces.<sup>6</sup> They are the acceptable and preferred implants in the treatment of proximal femoral fractures, specifically because they allow for a closed reduction procedure.<sup>7,8</sup> In addition, intramedullary fixation is associated with decreased soft tissue trauma, decreased blood loss, and lower rates of infection and wound complications.<sup>9</sup>

This study evaluates the clinical results, radiographic findings, and associated complications in patients who underwent osteosynthesis with PFN for fracture of the proximal femur.

**MATERIALS & METHODS**

The present study done on 152 patients (152 hips) who were followed up for at least 6 months were included in the study.

According to the AO/OTA classification criteria, A1, A2, and A3 type fractures were found in 22 (14.47%), 109 (71.71%), and 21 (13.8%) patients, respectively. Surgery was performed under spinal anesthesia using fluoroscopy-guided closed reduction on a traction table. All patients were ambulated on the first day after surgery with partial weight-bearing according to their pain tolerance levels. The mean duration of hospital stay was 6.05 (range 1–24) days. Postoperative reduction was assessed using the Baumgaertner et al’s scale.<sup>9</sup>

Functional results were evaluated using the Salvati and Wilson assessment score (SWS).<sup>10</sup> After the follow-up period, clinical and radiographic results were evaluated and the complications were assessed. Intraoperative complications were excluded.

Late complications, including implant cutout, Z-effect, reverse Z-effect, calcification of the tip of the greater trochanter, femoral neck shortening, nonunion, malunion, cortical thickening at the distal locking region, broken locking screw, broken PFN, and diaphyseal femoral fractures, were considered during radiographic assessment. The relationship between the complications and SWS score, age, sex, fracture type, reduction quality, and time from fracture to surgery was evaluated. The informed written consent was obtained from all the patients.

**RESULTS**

Our study showed that the, 90 (59.21%) were females and 62 (40.78%) were males. The mean age was 74 (range 21–93) years, and the mean follow-up duration was 23.2 (range 7–49) months. 72 patients (47.36%) had left hip fractures, and 80 (52.63%) had right hip fractures. The mechanism of fracture was a simple fall in 146 patients (96.1%), a car accident in four patients (2.6%), and a motorcycle accident in two patients (1.3%). The mean duration of the operation was 63.26 (range 50–85) minutes (table 1).

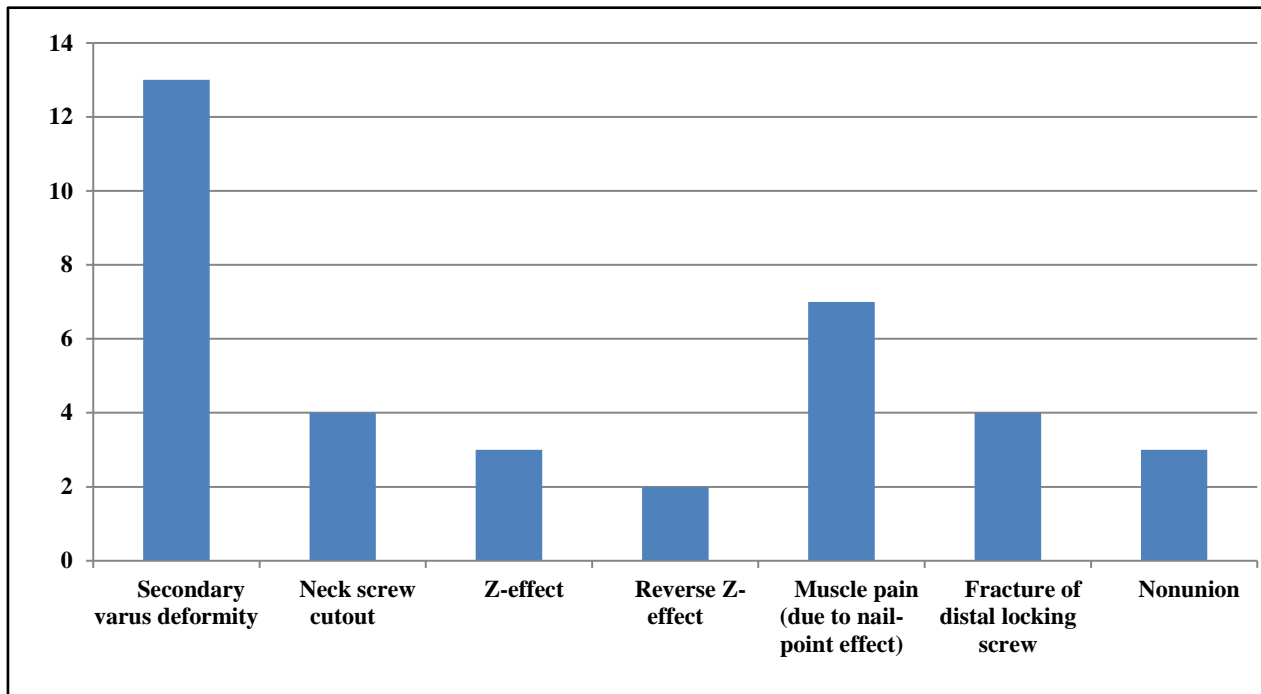
The initial postoperative radiographic assessment revealed that reduction was poor in one patient (0.6%), acceptable in 16 patients (10.5%), and good in 135 patients (88.9%). The SWS scores were excellent, good, moderate, and poor in 91 (59.8%), 45 (29.6%), 15 (9.8%), and one (0.6%) patients, respectively.

**Table 1: Demographic profile of patients**

<b>Number of patients</b>	<b>152</b>
<b>Mean age (yrs)</b>	74 yrs
<b>Female: Male</b>	1.45:1
<b>Location</b>	<b>Right Hip</b> 80 (52.63%)
	<b>Left Hip</b> 72 (47.36%)
<b>Type of fracture</b>	<b>A1</b> 22 (14.47%)
	<b>A2</b> 109 (71.71%)
	<b>A3</b> 21 (31.81%)

**Table 2: Late complications and surgical procedures**

<b>LATE COMPLICATIONS AND SURGICAL PROCEDURES</b>	<b>Cases</b>
<b>LATE COMPLICATIONS</b>	
Secondary Varus Deformity	13
Neck Screw Cutout	4
Z-Effect	3
Reverse Z-Effect	2
Muscle Pain (Due To Nail-Point Effect)	7
Fracture of Distal Locking Screw	4
Nonunion	3
<b>SURGICAL PROCEDURES</b>	
Partial Hip Arthroplasty	6
DCS	1
Shortening of Femoral Head Screw	1
Total Hip Arthroplasty	2
Removal of PFN	1
Removal of Femoral Head Screws	3

**Fig 1: Late complications**

A total of seven patients (4.6%) had thigh pain due to the nail-point effects. Femoral head screws were shortened in one patient (0.6%) because they caused trochanteric bursitis due to nail-point effect. The nail was removed in another patient (0.6%) because of nail-point-effect-related femoral fractures, and the patient underwent partial hip arthroplasty.

The SWS score was not significantly associated with the fracture type, age, sex, and time from fracture to surgery ( $P = 0.051$ ,  $P = 0.628$ ,  $P = 0.608$ , and  $P = 0.462$ , respectively). A postoperative SWS score of very good correlated with an excellent reduction in the early postoperative stage. We found a significant association between SWS score and reduction quality ( $\chi^2=35.446$ ,  $P=0.000$ ).

## DISCUSSION

Our study showed that the, 90 (59.21%) were females and 62 (40.78%) were males. The mean age was 74 (range 21–93) years, and the mean follow-up duration was 23.2 (range 7–49) months. According to the AO/OTA classification criteria, A1, A2, and A3 type fractures were found in 22 (14.47%), 109 (71.71%), and 21 (13.8%) patients, respectively.

In a study including 295 patients, Domingo et al<sup>6</sup> reported that ten patients (3.3%) who required a revision procedure had AO type 2 and type 3 fractures. Similarly, Simmermacher et al<sup>11</sup> concluded that PFN-related complications were mostly associated with AO type 2 fractures. In the present study, among 16 patients with moderate or poor SWS scores, 13 and three had AO type 2 and type 3 fractures, respectively. Of the patients who underwent revision, one patient had type

A1 fractures, eight patients had type A2 fractures, and four patients had type A3 fractures. In a series of 191 fractures, Simmermacher et al<sup>11</sup> reported an overall technical failure rate of 4.6%. In another study including 178 patients, Appelt et al<sup>12</sup> reported a complication rate of 15.2% ( $n=27$ ). In a case series including 47 peritrochanteric fractures, Fogagnolo et al<sup>2</sup> found mechanical failures in 23.4% patients ( $n=11$ ). In another case series including 80 patients, Akan et al<sup>7</sup> observed technical complications in 10% patients ( $n=8$ ). In a prospective study including 55 patients treated with PFN, Boldin et al<sup>13</sup> reported a complication rate of 21.8% patients ( $n=12$ ). Similar to the previous findings, our study showed that the rate of late complications following surgery was 17.7% (27 patients).

As a result, PFN is a relatively easy-to-use and effective device in the treatment of unstable trochanteric femoral fractures.<sup>6,8</sup> It enables early postoperative ambulation with a biomechanically stable structure.<sup>6</sup> In addition to using an appropriate implant, adequate reduction quality, proper implant insertion, and the experience of the surgeon play a key role in the successful osteosynthesis for trochanteric fractures.<sup>14-16</sup> Windolf et al<sup>14</sup> reported that the major causes of poor outcomes included poor fracture reduction and the use of an inappropriate screw. Osteosynthesis with PFN is a safe method for simple trochanteric fractures with excellent bone quality; however, PFN may not be the preferred method of fixation for complex fractures in patients with poor bone quality.<sup>12</sup> In our study, poor reduction was significantly associated with increased mechanical failure and revision rates. However, the fracture type was not significantly associated with mechanical failure.

## CONCLUSION

We concluded that the quality of fracture reduction is an important factor that affects the revision rate and SWS score in patients with mechanical complications after PFN was used for proximal fractures of femur.

## REFERENCES

1. Gustilo RB, Merkow RL, Templeman D. The management of open fractures. *J Bone Joint Surg (Am)*. 1990;72-A:299–304.
2. McKibbin B. The biology of fracture healing in long bones. *J Bone Joint Surg Br*. 1978;60:150–62.
3. Kenwright J, Richardson K, Spriggins AJ. Mechanical healing patterns of tibial fractures treated using different mechanical environments. *EUR SOC Biomech*. 1986; 5:173.
4. Müller ME, Nazarian S, Koch P, Schatzker J. *The Comprehensive Classification of Fractures of Long Bones*. Berlin, Germany: Springer-Verlag; 1990.
5. Menezes DF, Gamulin A, Noesberger B. Is the proximal femoral nail a suitable implant for treatment of all trochanteric fractures? *Clin Orthop Relat Res*. 2005;439:221–227.
6. Domingo LJ, Cecilia D, Herrera A, Resines C. Trochanteric fractures treated with a proximal femoral nail. *Int Orthop*. 2001;25(5):298–301.
7. Akan K, Cift H, Ozkan K, Eceviz E, Tasyikan L, Eren A. Effect of osteoporosis on clinical outcomes in intertrochanteric hip fractures treated with a proximal femoral nail. *J Int Med Res*. 2011;39(3):857–865.
8. Ozkan K, Unay K, Demircay C, Cakir M, Eceviz E. Distal unlocked proximal femoral intramedullary nailing for intertrochanteric femur fractures. *Int Orthop*. 2009;33(5):1397–1400.
9. Baumgaertner MR, Curtin SL, Lindskog DM. Intramedullary versus extramedullary fixation for the treatment of intertrochanteric hip fractures. *Clin Orthop Relat Res*. 1998;348:87–94.
10. Salvati EA, Wilson PD. Long term results of femoral-head replacement. *J Bone Joint Surg*. 1973;55(3):516–524.
11. Simmermacher RK, Bosch AM, Van der Werken C. The AO/ASIF-proximal femoral nail (PFN): a new device for the treatment of unstable proximal femoral fractures. *Injury*. 1999;30(5):327–332.
12. Appelt A, Suhm N, Baier M, Meeder PJ. Complications after intramedullary stabilization of proximal femur fractures: a retrospective analysis of 178 patients. *Eur J Trauma Emerg Surg*. 2007;33(3):262–67.
13. Boldin C, Seibert FJ, Fankhauser F, Peicha G, Grechenig W, Szyszkowitz R. The proximal femoral nail (PFN)-a minimal invasive treatment of unstable proximal femoral fractures: a prospective study of 55 patients with a follow-up of 15 months. *Acta Orthop Scand*. 2003;74(1):53–58.
14. Windolf J, Hollander DA, Hakimi M, Linhart W. Pitfalls and complications in the use of the proximal femoral nail. *Langenbecks ArchSurg*. 2005;390(1):59–65.
15. Baumgaertner MR, Curtin SL, Lindskog DM, Keggi JM. The value of the tip-apex distance in predicting failure of peritrochanteric fractures of the hip. *J Bone Joint Surg Am*. 1995;77(7):1058–1064.
16. Biber R, Grüninger S et al. Is proximal femoral nailing a good procedure for teaching in orthogeriatrics? *Arch Orthop Trauma Surg*. 2012;132(7):997–1002.

**Copyright:** © the author(s) and publisher IJMRP. This is an open access article distributed under the terms of the Creative Commons Attribution Non-commercial License, which permits unrestricted non-commercial use, distribution, and reproduction in any medium, provided the original work is properly cited.

**How to cite the article:** Indranil Dutt. Retrospective Evaluation of Complications Occurring in Patients Undergoing Proximal Femoral Nail Fixation. *Int J Med Res Prof*. 2015, 1(2); 96-99.