

## Assessment of Emergency Department Ultrasounds for Appendicitis: A Retrospective Analysis

**Rajeev Nagi**

Assistant Professor, Department of Radiology,  
Dr. Pinnamaneni Siddhartha Institute of Medical Sciences & Research Foundation,  
Vijayawada, Andhra Pradesh, India.

### Article History

Received: 10 July 2015

Revised: 01 Aug 2015

Accepted: 22 Aug 2015

### \*Correspondence to:

Dr. Rajeev Nagi,  
Assistant Professor,  
Department of  
Radiology,  
Dr. Pinnamaneni  
Siddhartha Institute of  
Medical Sciences &  
Research Foundation,  
Vijayawada, Andhra  
Pradesh, India.

### ABSTRACT

**Background:** Appendicitis is one of the common and serious problems occurring in the abdominal causing severe abdominal pain in adolescents and young adults who are routinely admitted to the emergency departments. One of the common cause of appendicitis is luminal obstruction which is created by luminal obstruction, thereby leading to distension, increased intraluminal pressure, and mucosal compromise with subsequent mural invasion by intraluminal bacteria. Despite the advancements in the diagnostic technologies and clinical strategies, still false positive and false negative results in making the diagnosis of acute appendicitis are significantly reported. Hence; we carried this retrospective study to analyze whether Emergency doctors are skilled enough to perform ultrasounds and other related applications in diagnosing the patients with acute appendicitis.

**Materials & Methods:** The present retrospective study was conducted in the department of Radiology and emergency medicine, Dr. Pinnamaneni Siddhartha Institute of Medical Sciences & Research Foundation, Vijayawada, Andhra Pradesh (India) and included assessment of all the patients that were admitted with the chief problem of appendicitis. Data of all the patients was included which were admitted in the medical hospital and in whom right lower quadrant (RQ) abdominal ultrasounds performed by Emergency doctors (ED). In the emergency departments (EDT) every year, on an average, 1200 EDs performed EDT ultrasounds which were taped on video followed by reviewing by the Director of Emergency Ultrasound (JCF) for accuracy. We assessed the specificity, sensitivity and predictive values along with the confidence intervals.

**Results:** A total of 72 patients showed positive results for bedside ultrasound for appendicitis (BA). Out these 72 patients, 54 were actually affected by appendicitis while in 18 patients, appendicitis was absent. A total of 238 patients were reported to be BA negative. Out of them in 84 and 154 patients, appendicitis was present and absent respectively. In total, out of 310 total patients, 138 cases showed presence of appendicitis while in 172 cases, appendicitis was absent. Prevalence in the present study was found to be 0.46 while the specificity and the sensitivity were found to be 0.92 and 0.41 respectively. Positive predictive values and the negative predictive values were found to be 0.77 and 0.68 respectively in the present study.

**Conclusion:** Without giving proper training and instructions to the EDs for BA, the reliability of diagnosis of patients with right lower abdominal pain by these physicians cannot be confirmed.

**KEYWORDS:** Appendicitis, Emergency, Ultrasound.

### INTRODUCTION

In adolescents and young adults who are routinely admitted to the emergency departments of the medical hospitals, one of the common and serious problems

occurring in the abdominal causing severe abdominal pain is the appendicitis. Luminal obstruction is one of the most common causes of acute appendicitis, which

further lead to distension, increased intraluminal pressure, and mucosal compromise with subsequent mural invasion by intraluminal bacteria.<sup>1</sup>

Peritonitis and even death can result from gangrene and perforation which occurs due to increase in pressure and venous obstruction. Early surgical intervention in patients with acute appendicitis is imperative to avoid appendiceal perforation, which is associated with increased morbidity and mortality. Duration of symptoms is the factor most closely associated with advanced disease.<sup>2</sup>

Since, the sensitivity and specificity yielded by clinical evaluation alone varies a lot, it remains a wide challenge regarding the diagnosis by Emergency Doctors (ED). Despite the advancements in the diagnostic technologies and clinical strategies, still false positive and false negative results in making the diagnosis of acute appendicitis are significantly reported.<sup>3</sup> Moreover, perforated appendicitis, with its 4% mortality rate, is the most common abdominal disorder for malpractice claims and the fifth most expensive cause of claims against emergency physicians.<sup>4</sup> Perforation often results due to the delay in the diagnosis of the pathology.<sup>5</sup>

Hence; we carried this retrospective study to analyze whether ED are skilled enough to perform ultrasounds and other related applications in diagnosing the patients with acute appendicitis.

## MATERIALS & METHODS

The present retrospective study was conducted in the department of Radiology and emergency medicine, Dr. Pinnamaneni Siddhartha Institute of Medical Sciences & Research Foundation, Vijayawada, Andhra Pradesh (India) and included assessment of all the patients that were admitted with the chief problem of appendicitis. Data of all the patients was included which were admitted in the medical hospital and in whom right lower quadrant (RLQ) abdominal ultrasounds performed by Emergency doctors (ED).

Important point of question was that whether ED had strong knowledgeable practice in applications involving ultrasound techniques. Also question was that whether these EDs without having experience and training for appendicitis, could diagnose appendicitis with reasonable accuracy. The involved EDs had training in

the diagnosis and treatment of the lesions of the gall bladder, aorta, cardiac region, pelvis etc. but didn't have much exposure to appendicitis. 28 EDs were initially included in the present study out of which six were registered to Registered Diagnostic Medical Sonographers (RDMS). A minimum of 600 ultrasounds were performed by the 14 of the included EDs which included ultrasounds of various organs. Only those cases were included in this retrospective analysis in which confirmation of the diagnosis was given team of Radiologists. Prior to graduation, residents are required to fulfil the quota of minimum of 500 scans of all the types. No additional information and hands-on instruction was given to the ED regarding the technique of ultrasound.

Ethical approval was taken from the institutional ethical committee and written consent was obtained after explaining in detail the entire research protocol. In the emergency departments (EDT) every year, on an average, 1200 EDs performed EDT ultrasounds which were taped on video followed by reviewing by the Director of Emergency Ultrasound (JCF) for accuracy. Board certification of all the attending EDs was done. Exclusion criteria included patients in which CT scan with oral and IV contrast was performed or patients in whom the pathology report indicated laprotomy. Prior to the occurrence of radiology ultrasound and/or Computed Tomography (CT), all the EDT ultrasounds were performed.

Non-compressible RLQ tubular structure of at least six millimetres was the whole and sole primary sonographic criterion for the EDs for arriving to the final diagnosis of appendicitis. Other features and sonographic findings which were excluded from the list of primary criterion and were included under the category of secondary features included:

- Appendicolith,
- Extraluminal fluid collections,
- Hyperemia on color flow Doppler,
- Interruption of the echogenic submucosa.

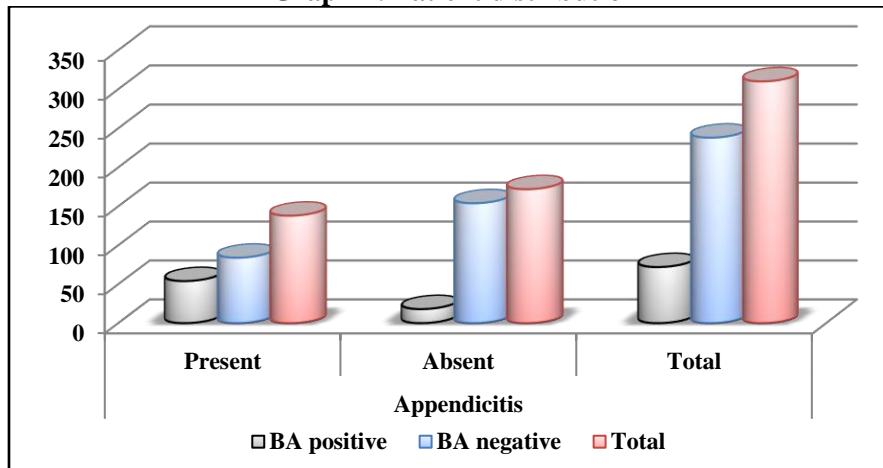
All the results were analyzed by SPSS software. Univariate analysis was used for the assessment of level of significance. We also assessed the specificity, sensitivity and predictive values along with the confidence intervals.

**Table 1: Distribution of the patients**

| Parameter    | Appendicitis |        |       |
|--------------|--------------|--------|-------|
|              | Present      | Absent | Total |
| BA positive  | 54           | 18     | 72    |
| BA negative  | 84           | 154    | 238   |
| <b>Total</b> | 138          | 172    | 310   |

BA: Bedside Ultrasound for Appendicitis

**Graph 1: Patient distribution**



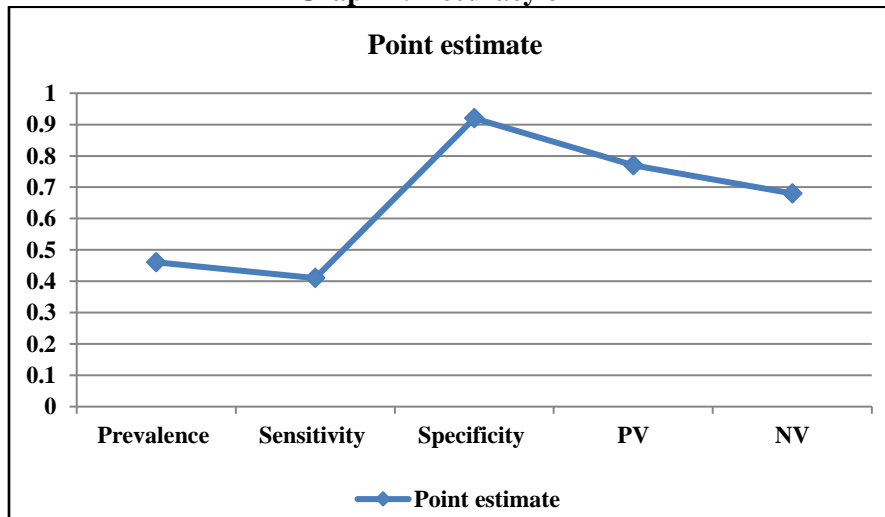
BA: Bedside Ultrasound for Appendicitis

**Table 2: Specificity and accuracy of BA**

| BA's accuracy | Point estimate | 95 percent CI |      |
|---------------|----------------|---------------|------|
| Prevalence    | 0.46           | 0.38          | 0.55 |
| Sensitivity   | 0.41           | 0.29          | 0.54 |
| Specificity   | 0.92           | 0.82          | 0.97 |
| PV            | 0.77           | 0.58          | 0.88 |
| NV            | 0.68           | 0.56          | 0.74 |

CI: Confidence interval, PV: Positive predictive value, NV: Negative predictive value, BA: Bedside Ultrasound for Appendicitis

**Graph 2: Accuracy of BA**



PV: Positive predictive value, NV: Negative predictive value, BA: Bedside Ultrasound for Appendicitis

**RESULTS**

A total of 372 RO ultrasounds were performed by the EDs for the problem of appendicitis during the study period. Graph 1 highlights the distribution of the patients. A total of 72 patients showed positive results for bedside ultrasound for appendicitis (BA). Out these 72 patients, 54 were actually affected by appendicitis while in 18 patients, appendicitis was absent. A total of 238 patients were reported to be BA negative. Out of them in 84 and 154 patients, appendicitis was present and absent respectively. In total, out of 310 total patients, 138 cases showed presence of appendicitis

while in 172 cases, appendicitis was absent. Table 2 and Graph 2 shows the accuracy of BA. Prevalence in the present study was found to be 0.46 while the specificity and the sensitivity were found to be 0.92 and 0.41 respectively. Positive predictive values and the negative predictive values were found to be 0.77 and 0.68 respectively in the present study.

**DISCUSSION**

One of the common causes of the occurrence of abdominal pain is the Appendicitis. More than 250,000 cases of appendicitis are diagnosed in the United States

each year, and appendectomy is the most frequent emergent surgery performed worldwide.<sup>6-8</sup> Despite of its high frequency of occurrence, the diagnosis can be elusive and fraught with pitfalls because of the absence of a pathognomonic sign or symptom, the poor predictive value of associated laboratory testing, and its varied presentation diagnosis.<sup>9-11</sup> Since 1981, Ultrasound has been used for the diagnosis of acute appendicitis. Technologic improvements in ultrasound equipment have made systems more portable, easier to use at the bedside and of higher image quality, enhancing the accuracy of diagnosis. It is a risk free, low-cost, noninvasive, fast and painless procedure that does not use ionizing radiation and can be done at the bedside.<sup>12,13</sup> The diagnosis of appendicitis is made by graded compression technique that was first described by Puylaert in 1986. A linear high-frequency transducer is placed on the right lower quadrant and pressure is applied gradually while imaging, displacing the overlying gas-filled loops of bowel.<sup>14</sup> Bedside ET ultrasound is becoming widely available. Ultrasound training is required in emergency physicians have demonstrated the ability to accurately perform focused ultrasound examinations.<sup>15,16</sup> Hence; we carried this retrospective study to analyze whether ED are skilled enough to perform ultrasounds and other related applications in diagnosing the patients with acute appendicitis.

In the present study we observed a specificity and sensitivity of 0.92 and 0.41 respectively which indicate that BA should be performed by only those ED who have received proper training of ultrasound and other related applications. Ramarajan et al analyzed the interdisciplinary initiative to use a staged Ultrasonography and Computed tomography pathway to maximize diagnostic accuracy while minimizing radiation exposure. From this retrospective analysis, they concluded that half of the patients who were treated using this pathway were managed with definitive US alone with an acceptable negative appendectomy rate and a missed appendicitis rate of less than 0.5%.<sup>17</sup> Fox et al assessed the accuracy of emergency physicians using bedside ultrasound to detect appendicitis (BA). From the results, they concluded that insufficient evidence exists which could support the use of bedside ultrasound by emergency physicians to rule out appendicitis.<sup>18</sup> Estey et al assessed the value of the nonvisualized appendix on ultrasound and the association of secondary sonographic findings in pediatric patients with acute right lower quadrant pain. From the results they concluded that in the absence of a distinctly visualized appendix, the presence of multiple secondary inflammatory changes provides increasing support of a diagnosis of acute appendicitis.<sup>19</sup> Wiersma et al evaluated the additional value of secondary signs in the diagnosing of appendicitis in children with ultrasound. From the

results, they concluded that in case of non-visualization of the appendix without secondary signs, appendicitis can be safely ruled out.<sup>20</sup> Estey et al assessed the value of the nonvisualized appendix on ultrasound and the association of secondary sonographic findings. From the results, they concluded that although uncommonly seen, large amounts of free fluid and pericecal inflammatory fat changes were very specific signs of acute appendicitis.<sup>21</sup> Ang et al determined the accuracy of sonography in the diagnosis of clinically equivocal appendicitis. From the results, they concluded that ultrasound is a useful for the evaluation of acute abdominal pain in children.<sup>22</sup>

## CONCLUSION

From the above results, the authors concluded that without giving proper training and instructions to the EDs for BA, the reliability of diagnosis of patients with right lower abdominal pain by these physicians cannot be confirmed. However, future studies are recommended for better results.

## REFERENCES

1. Crawford JM. The Gastrointestinal Tract. In: Conran R, Kumar V, Collins T, editors. Robbins pathologic basis of disease. 6th edition. Philadelphia: Saunders; 1999. pp. 775–843.
2. Stabile Ianora AA, Lorusso F, Niccoli Asabella A, Di Maggio P, Fonio P, Losco M, Rubini G: Multidetector CT for the assessment of the groin region. *Recenti Prog Med* 2012, 103(11):483–8.
3. Paulson EK, Kalady MF, Pappas TN. Clinical practice. Suspected appendicitis. *N Engl J Med.* 2003 Jan 16;348(3):236-42.
4. Trautlein JJ, Lambert RL, Miller J. Malpractice in the Emergency Department--review of 200 cases. *Ann Emerg Med.* 1984; 13(9 Pt 1):709-11.
5. Roosevelt GE, Reynolds, SL. Does the use of ultrasonography improve the outcome of children with appendicitis? *Acad Emerg Med.* 1998;5(11):1071-5.
6. Reginelli A, Pezzullo MG, Scaglione M, Scialpi M, Brunese L, Grassi R: Gastrointestinal disorders in elderly patients. *Radiol Clin North Am* 2008, 46(4):755–71.
7. Pittman-Waller VA, Myers JG, Stewart RM, et al.: Appendicitis: why so complicated? Analysis of 5755 consecutive appendectomies. *Am Surg* 2006, 66: 548–555.
8. Vissers RJ, Lennarz WB: Pitfalls in appendicitis. *Emerg Med Clin N Am* 2010, 28: 103–118.
9. Reginelli A, Mandato Y, Cavaliere C, Pizza NL, Russo A, Cappabianca S, Brunese L, Rotondo A, Grassi R: Three-dimensional anal endosonography in depicting anal-canal anatomy. *Radiol Med* 2012, 117(5):759–71.
10. Angelelli G, Moschetta M, Cosmo T, Binetti F, Scardapane A, Stabile Ianora AA: CT diagnosis of the nature of bowel obstruction: morphological evaluation of the transition point. *Radiol Med* 2012, 117(5):749–58.
11. Lorusso F, Fonio P, Scardapane A, Giganti M, Rubini G, Ferrante A, Stabile Ianora AA: Gastrointestinal imaging

with multidetector CT and MRI. *Recenti Prog Med* 2012, 103(11):493-9.

12. Brown MA. Imaging acute appendicitis. *Semin Ultrasound CT MR*. 2008;29:293-307.

13. Lindelius A, Torngren S, Pettersson H, et al. Role of surgeon-performed ultrasound on further management of patients with acute abdominal pain: a randomised controlled clinical trial. *Emerg Med J*. 2009;26:561-566.

14. Doria AS, Moineddin R, Kellenberger CJ, et al. US or CT for Diagnosis of Appendicitis in Children and Adults? A Meta-Analysis. *Radiology*. 2006;241:83-94.

15. Min YG, Lee CC, Bae YS, et al. Accuracy of sonography performed by emergency medicine residents for the diagnosis of acute appendicitis. *Ann Emerg Med*. 2004;44:S60.

16. Pinto A, Caranci F et al: Learning from errors in radiology: a comprehensive review. *Semin Ultrasound CT MRI* 2012, 33: 379-382.

17. Ramarajan N, Krishnamoorthi R, Barth R, Ghanouni P, Mueller C, Dannenburg B, Wang NE. An interdisciplinary initiative to reduce radiation exposure: evaluation of appendicitis in a pediatric emergency department with clinical assessment supported by a staged ultrasound and computed tomography pathway. *Acad Emerg Med*. 2009 Nov;16(11):1258-65.

18. Fox JC, Solley M, Anderson CL, Zlidenny A, Lahham S, Maasumi K. Prospective evaluation of emergency

physician performed bedside ultrasound to detect acute appendicitis. *Eur J Emerg Med*. 2008 Apr;15(2):80-5.

19. Estey A, Poonai N, Lim R. Appendix not seen: the predictive value of secondary inflammatory sonographic signs. *Pediatr Emerg Care*. 2013 Apr;29(4):435-9.

20. Wiersma F, Toorenvliet BR, Bloem JL, Allema JH, Holscher HC. US examination of the appendix in children with suspected appendicitis: the additional value of secondary signs. *Eur Radiol*. 2009 Feb;19(2):455-61.

21. Estey A, Poonai N, Lim R. Appendix not seen: the predictive value of secondary inflammatory sonographic signs. *Pediatr Emerg Care*. 2013 Apr;29(4):435-9.

22. Ang A, Chong NK, Daneman A. Pediatric appendicitis in "real-time": the value of sonography in diagnosis and treatment. *Pediatr Emerg Care*. 2001 Oct;17(5):334-40.

**Copyright:** © the author(s) and publisher IJMRP. This is an open access article distributed under the terms of the Creative Commons Attribution Non-commercial License, which permits unrestricted non-commercial use, distribution, and reproduction in any medium, provided the original work is properly cited.

**How to cite the article:** Rajeev Nagi. Assessment of Emergency Department Ultrasounds for Appendicitis: A Retrospective Analysis. *Int J Med Res Prof*. 2015, 1(2); 87-91.