

# Rescue Intubation with I-gel for Airway Management of Neonates with Pierre Robin Sequence Who Underwent Glossopexy Procedure: A Prospective Study

Irshad Ahmad<sup>1</sup>, Iram Jan<sup>2\*</sup>, Masroor Khurshied Shah<sup>3</sup>

<sup>1</sup>Associate Professor, Department of Oral and Maxillofacial Surgery, Government Dental College & Hospital, Srinagar, J&K, India.

<sup>2</sup>MDS Oral and Maxillofacial Surgery, Srinagar, J&K, India.

<sup>3</sup>Post Graduate Scholar, Department of Oral and Maxillofacial Surgery, Government Dental College & Hospital, Srinagar, J&K, India.

## ABSTRACT

**Background:** Neonates and infants with Pierre Robin sequence and its associated syndromes may present upper airway obstruction and feeding difficulties very early in life because of glossoptosis and micrognathia. Hence, the present study was conducted to assess the rescue intubation with I-gel for airway management of neonates with Pierre Robin sequence that underwent glossopexy procedure.

**Materials & Methods:** A total of 10 subjects who reported to the Post graduate Department of Oral and Maxillofacial Surgery, Govt. Dental College and Hospital, Srinagar were selected for glossopexy who demonstrated upper airway obstruction with desaturation that was not relieved by the prone positioning and required a nasopharyngeal tube placement. There was no premedication given. With a nasopharyngeal tube in place, anesthesia was induced in all patients using a mask containing sevoflurane and nitrous oxide in oxygen. The protocol was to apply a "Tongue traction stitch" and then attempt two direct laryngoscope intubations, two fiberoptic endoscope intubations, and finally introduce I-gel™ to manage the problematic airway throughout the glossopexy surgery.

**Results:** Intubation with direct laryngoscope was done in 20 percent of the patients while 30 percent and 50 percent of the patients were intubated with fiberoptic endoscope and I-gel™, respectively. Using this airway management technique during

glossopexy allowed for the successful treatment of a challenging airway with no postoperative problems. However, with other techniques postoperative complications such as minor symptoms of upper airway obstruction were noticed. Also, I-gel™ has an added advantage of preventing aspiration of gastric content.

**Conclusion:** For such individuals, I-gel™ is a viable substitute that offers a dependable and safe airway access to perform the glossopexy surgery.

**Key words:** Pierre Robin sequence (PRS), Glossopexy, Fairbairn–Robin triad (FRT), Isolated Cleft Palate (ICP).


## \*Correspondence to:

**Dr. Iram Jan,**  
MDS Oral and Maxillofacial Surgery,  
Srinagar, J&K, India.  
miriram3nov@gmail.com

## Article History:

Received: 12-02-2024, Revised: 03-03-2024, Accepted: 27-03-2024

## Access this article online

Website: <a href="http://www.ijmrp.com">www.ijmrp.com</a>	Quick Response code 
DOI: 10.21276/ijmrp.2024.10.2.001	

## INTRODUCTION

In 1923, Pierre Robin, a French stomatologist, documented a disorder which now bears his namesake. Pierre Robin sequence (PRS) was originally described as consisting of micrognathia (which he termed "mandibular hypotrophy") and glossoptosis (an abnormal posterior placement of the tongue), which result in airway obstruction and feeding difficulties. The small mandible is thought to be due to an inherent genetic problem or a deformational problem where intrauterine growth is restricted or mandibular positioning is altered.<sup>1-3</sup> A proportion of PRS infants do not respond to conservative measures and will require further intervention. Prior to considering any surgical procedure, the

clinician should first rule out any sources of obstruction below the base of the tongue that would necessitate a tracheostomy.<sup>4,5</sup> Neonates and infants with Pierre Robin sequence and its associated syndromes may present upper airway obstruction and feeding difficulties very early in life because of glossoptosis and micrognathia. If these conditions are severe and not improved by nonsurgical approaches such as prone positioning, supplemental oxygen, temporary nasopharyngeal tube placement, or nasogastric feeding, surgical management will be considered. Glossopexy (tongue-lip adhesion) is a procedure in which the tongue is anchored to the lower lip and mandible to prevent the

posterior displacement of the tongue and relieve the upper airway obstruction. The main purpose of the glossopexy is the avoidance of tracheostomy which has been utilized as a treatment of last resort, but sometimes associated with serious complications.<sup>6-8</sup> hence; the present study was conducted for assessing the rescue intubation with I-gel for airway management of neonates with Pierre Robin sequence that underwent glossopexy procedure.

**MATERIALS & METHODS**

The present study was conducted for assessing the rescue intubation with I-gel for airway management of neonates with Pierre Robin sequence that underwent glossopexy procedure. A total of 10 subjects, who reported to the Post graduate Department of Oral and Maxillofacial Surgery, Govt. Dental College and Hospital, Srinagar fulfilling the inclusion criteria were included. The study protocol was approved by the Institutional Ethical Committee and Review Board. Written and verbal consent was obtained from the selected patients. The subjects were selected for glossopexy, who demonstrated upper airway obstruction with desaturation that was not relieved by the prone positioning and required a nasopharyngeal tube placement. There was no premedication given. With a nasopharyngeal tube in place, anesthesia was induced in all patients using a mask containing

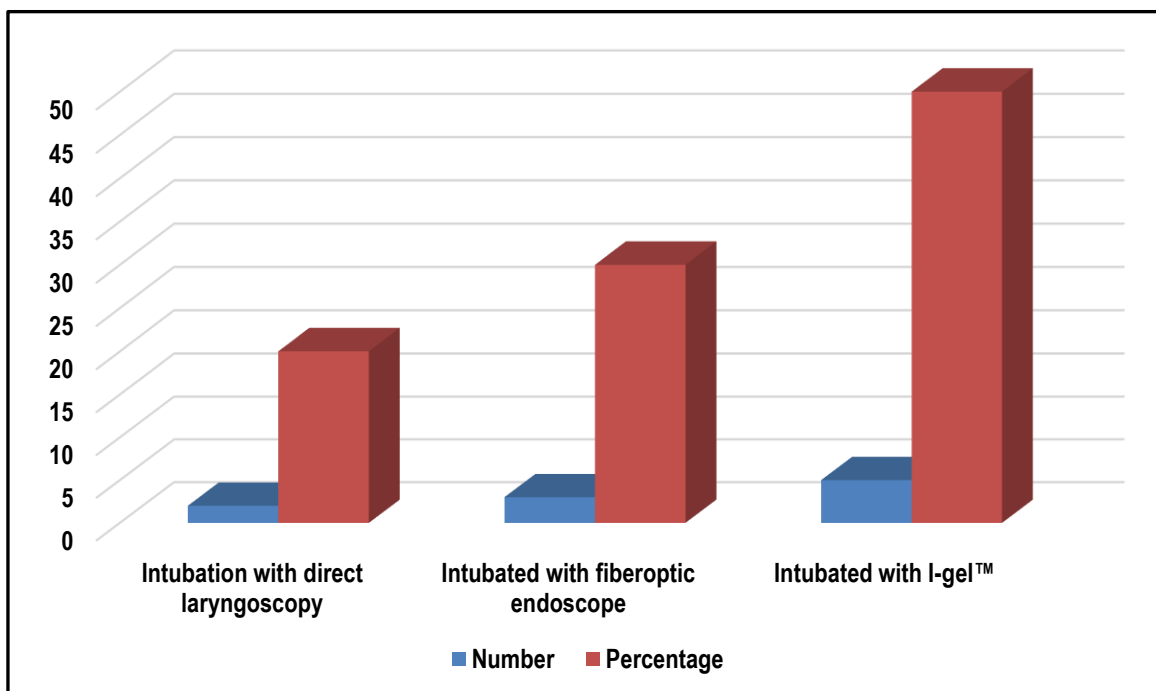
sevoflurane and nitrous oxide in oxygen. Sevoflurane or isoflurane was then used to maintain anesthesia. 1% lidocaine and a 1:160,000 dilution of epinephrine solution were infused into the surgical site prior to the patients undergoing the glossopexy surgery, which involved moving the tongue forward, attaching it to the mandible, and suturing it to the lower lip. The protocol was to apply a "Tongue traction stitch" and then attempt two direct laryngoscope intubations, two fiberoptic endoscope intubations, and finally introduce I-gel™ to manage the problematic airway throughout the glossopexy surgery. All the results were recorded in Microsoft excel sheet and was subjected to statistical analysis using SPSS software.

**RESULTS**

Intubation with direct laryngoscope was done in 20 percent of the patients while 30 percent and 50 percent of the patients were intubated with fiberoptic endoscope and I-gel™. Using this airway management technique during glossopexy allowed for the successful treatment of a challenging airway with no postoperative problems. However, with other techniques postoperative complications such as minor symptoms of upper airway obstruction were noticed. Also, I-gel™ has an added advantage of preventing aspiration of gastric content.

**Table 1: Distribution of cases according to type of intubation**

Type of intubation	Number	Percentage
Intubation with direct laryngoscopy	2	20
Intubated with fiberoptic endoscope	3	30
Intubated with I-gel™	5	50
Total	10	100



**Figure 1: Distribution of cases according to type of intubation**

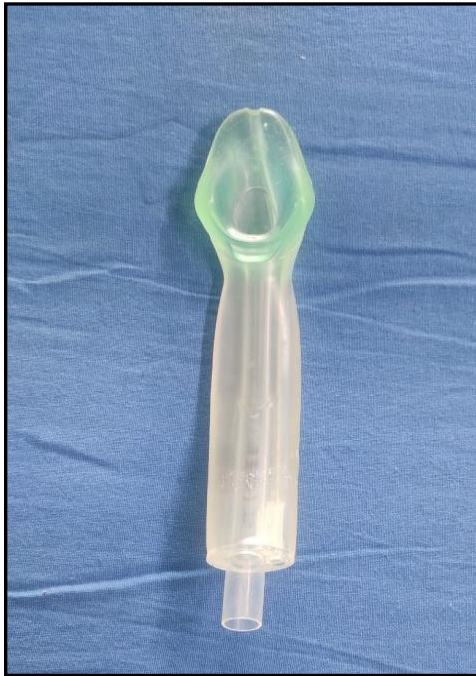

Figure 2: I-gel™

## DISCUSSION

It has been stated that the presence of a wide and U-shaped cleft justifies the diagnosis of a Fairbairn–Robin triad (FRT). Amaratunga found that similar proportions of U- and V-shaped clefts were present amongst both the FRT and (Isolated Cleft Palate) ICP groups; whereas some authors even specify that the type of cleft should be wide and U-shaped to justify the diagnosis. The wide U-shaped cleft palate (FRT) is certainly not an essential element for the diagnosis. According to the data analyzed from this cleft clinic database, eight cases presented with glossoptosis, a tongue that was folded sagittal and lodged into a relatively narrow palatal cleft 7 hard and soft palate (hPsP), 1 soft palate (sP). One additional case with an sP cleft, presented with the tongue folded coronally and positioned posteriorly against the superior part of the sP and not into relatively narrow sP cleft.<sup>9-12</sup> Hence; the present study was conducted for assessing the rescue intubation with I-gel for airway management of neonates with Pierre Robin sequence who underwent glossopexy procedure. Intubated with direct laryngoscope was done in 20 percent of the patients while 30 percent and 50 percent of the patients were intubated with fiberoptic endoscope and I-gel™. Using this airway management technique during glossopexy allowed for the successful treatment of a challenging airway with no postoperative problems. Shetty V et al reviewed the utility of I-gel as a successful airway management device for infants with Pierre robin sequence (PRS) undergoing glossopexy. A prospective study was conducted on PRS neonates. The algorithm followed was putting a 'Tongue traction stitch' followed by the following sequence - two trials with direct laryngoscope intubation, two attempts with fiberoptic endoscope intubation followed by insertion of I-gel™ to manage difficult airway during glossopexy procedure. 6 patients were intubated with direct laryngoscope, 12 patients were intubated with fibreoptic endoscope, and the rest 13 patients were intubated using I-gel™. Successful management of difficult airways was achieved with this airway management protocol during glossopexy and nil postoperative complications were

encountered. They concluded that, I-gel™ is a relevant alternative to provide a reliable and secure airway access to carry out glossopexy procedure in such patients.<sup>13</sup> Fujii M et al retrospectively examined the perioperative management of 19 infants undergoing glossopexy procedure. Out of 19 patients, Pierre Robin sequence was diagnosed in 17, Treacher Collins syndrome in 1, and Stickler syndrome in 1. In all of them, inhalation anesthesia was induced with a nasopharyngeal tube in place. Nine patients underwent fiberoptic intubation. After surgery, 12 patients were extubated in the operating room and 11 of them required a nasopharyngeal tube to keep the airway open. Seven patients left the operating room with the trachea intubated. Two patients received tracheostomy at the age of 2 months. Seventeen patients underwent release of tongue-lip adhesion coincidentally with the palate repair at 7-14 months of age. For this surgery, no one required fiberoptic intubation. The airway of these patients should be managed carefully not only before but also after the operation.<sup>14</sup> Naros A et al evaluated perioperative complications following their institutional pre- and intraoperative management in cleft palate repair with Robin sequence (RS). RS patients who underwent cleft palate repair between 2000 and 2020 were retrospectively analysed. RS children with complete documentation and whose initial treatment involved the Tuebingen palatal plate (TPP) were included. 143 RS patients (41% male, 59% female) were included. Median pretherapeutic mixed-obstructive apnea index (MOAI) after birth was 9.4/hour (IQR 20.0). TPP treatment was associated with normalisation of the MOAI and adequate weight gain until surgery. At surgery, median age was 10 months (IQR 3), MOAI 0.1/h (IQR 0.5), and weight 8.7 kg (IQR 1.7). In 93% of cases (n = 133), the postoperative course was uneventful. Refinement of the anesthesiology protocol showed positive effects on the perioperative course and led to a reduction in perioperative events (10.7% vs. 2.9%). No severe perioperative complications occurred. They recommend the adoption of TPP treatment in the therapy of RS children.<sup>15</sup>

## CONCLUSION

I-gel™ is a simple, excellent and easy to use supraglottic airway device and viable substitute that offers dependable and safe airway access to perform the glossopexy surgery. It is easy to insert without need of many manipulations with maintenance of airway in a short time. Our study concludes that the I-gel provides a reasonable alternative to the ETT for controlled ventilation in patients undergoing routine surgical procedures. However more studies with a large number of patients are warranted to further validate our results before recommending its widespread use.

## REFERENCES

1. Sommerlad B. Philadelphia, PA: Saunders Elsevier; 2009. Cleft palate; pp. 508–9.
2. Mackay D R. Controversies in the diagnosis and management of the Robin sequence. *J Craniofac Surg.* 2011;22(2):415–20.
3. Skillman J, Cole A, Slator R. Sodium supplementation in neonates with Pierre Robin sequence significantly improves weight gain if urinary sodium is low. *Cleft Palate Craniofac J.* 2012;49(1):39–43.
4. Rogers G F, Murthy A S, LaBrie R A, Mulliken J B. The GILLS score: part I. Patient selection for tongue-lip adhesion in Robin sequence. *Plast Reconstr Surg.* 2011;128(1):243–51.

5. Hunt J A Hobar P C. Common craniofacial anomalies: the facial dysostoses *Plast Reconstr Surg* 2002; 110(7): 1714–25.
6. Evans KN, Sie KC, Hopper RA et al. Robin sequence: from diagnosis to development of an effective management plan. *Pediatrics* 2011; 127: 936–48.
7. Gangopadhyay N, Mendonca DA, Woo AS. Pierre Robin sequence. *Semin Plast Surg* 2012; 26: 76–82.
8. Singer L, Sidoti EJ. Pediatric management of Robin sequence. *Cleft Palate Craniofac J* 1992; 29: 220–3.
9. Wagener S, Rayatt S S, Tatman A J, Gornall P, Slator R. Management of infants with Pierre Robin sequence. *Cleft Palate Craniofac J*. 2003;40(2):180–5.
10. Shprintzen RJ. Pierre Robin, micrognathia, and airway obstruction: The dependency of treatment on accurate diagnosis. *Int Anesthesiol Clin*. 1988;26:64–71.
11. Amaratunga NA. A comparative clinical study of Pierre Robin syndrome and isolated cleft palate. *Br J Oral Maxillofac Surg*. 1989;27:451–8.
12. Bütow KW, Hoogendijk CF, Zwahlen RA. Pierre Robin sequence: Appearances and 25 years of experience with an innovative treatment protocol. *J Pediatr Surg*. 2009;44:2112–8.
13. Shetty V, Mehendale SG, Bhat M, Yadav A, Bahl D, Sailer H. Efficacy of I-gel™ for airway management of neonates with Pierre Robin sequence undergoing glossopexy: A prospective study. *J Craniomaxillofac Surg*. 2022;50(7):569-75.
14. Fujii M, Tachibana K, Takeuchi M, Nishio J, Kinouchi K. Perioperative management of 19 infants undergoing glossopexy (tongue-lip adhesion) procedure: a retrospective study. *Paediatr Anaesth*. 2015;25(8):829-33.
15. Naros A et al. Perioperative complications in cleft palate repair with Robin sequence following Tuebingen palatal plate treatment. *Journal of Cranio-Maxillofacial Surgery*. 2021; 49(4): 298- 303.

**Source of Support:** Nil. **Conflict of Interest:** None Declared.

**Copyright:** © the author(s) and publisher. IJMRP is an official publication of Ibn Sina Academy of Medieval Medicine & Sciences, registered in 2001 under Indian Trusts Act, 1882. This is an open access article distributed under the terms of the Creative Commons Attribution Non-commercial License, which permits unrestricted non-commercial use, distribution, and reproduction in any medium, provided the original work is properly cited.

**Cite this article as:** Irshad Ahmad, Iram Jan, Masroor Khurshied Shah. Rescue Intubation with I-gel for Airway Management of Neonates with Pierre Robin Sequence Who Underwent Glossopexy Procedure: A Prospective Study. *Int J Med Res Prof*. 2024 Mar; 10(2): 1-4. DOI:10.21276/ijmrp.2024.10.2.001