

# Morphological Study of Superficial Palmar Arches and Their Variations

Rakhee Yashwant Dhongade<sup>1\*</sup>, M. S. Farooqui<sup>2</sup>, R.N.Wabale<sup>3</sup>

<sup>1</sup>Tutor, <sup>2</sup>Professor, <sup>3</sup>Professor and Head, Department of Anatomy, PIMS' Rural Medical College, Loni, MH, INDIA.

## ABSTRACT

**Introduction:** The superficial palmar arch (SPA) is the main vascular structure of the palm, conventionally, the superficial palmar branch of the ulnar artery (SPUA), the superficial palmar branch of the radial artery (SPRA) and arteria radialis indices are described as contributing vessels in the formation of superficial palmar arch (SPA) with the ulnar artery as the main feeding vessel. Variations in SPA are more commonly reported in previous studies. The hand surgeon needs to refer to the existence and healthy function of the arch before various surgical procedures. So it is necessary to have knowledge about the various variations in formation of SPA to clinicians, hand surgeons and radiologist.

**Materials and methods:** **Type of the study:** Descriptive study, **study period:** 3 years **study setting:** Department of anatomy, PIMS' Rural Medical College, Loni. **Study Sample:** 177 hands received during the study period at Dept. of Anatomy for routine dissection for students at the institute having intact superficial and deep structures. The superficial palmar arches were dissected, cleaned and photographed. Palmar aponeurosis was exposed and separated. Variation were compared with normal patterns and were documented and photographed.

**Results:** Out of total 177 SPA dissected 99 specimens (55.93%) were having non-arch type SPA (incomplete arch) and 78 specimens (44.07%) were having arched type of SPA (Complete arch). Arch types of superficial palmar arches were further classified into 8 subtypes of arches: Ulnar – radiopalmar subtypes: Ulnar-radio pattern found in 27 (15.25%) hands, Classical pattern in 5 hands [2.82%], Ulnar +superficial radial +1<sup>st</sup> palmar metacarpal artery; in 6 hands (3.39%) , Ulnar + median palmar type found in - 8 hands (4.51%) , Ulnar +median +1<sup>st</sup> dorsal metacarpal artery in 1 hand (0.56%), Ulnar + 1<sup>st</sup> dorsal metacarpal artery in 9 hands (5.08%), Ulnar + 1<sup>st</sup> palmar metacarpal artery in 18 hands (10.16%), Ulnar + proper radial +1<sup>st</sup> dorsal metacarpal artery in 4 hands (2.26%). Non arch type further classified in to following subtypes: dominant

ulnar type and co-dominant types Dominant Ulnar type was observed In 62 hands (35.03%).

Co-dominant types further categorised under following subgroups: Ulnar + radiopalmar type in 12 hands ( 7.90%), Ulnar pattern in 2 hands (1.13%) , Ulnar + superficial radial +1<sup>st</sup> palmar metacarpal artery in 2 hands (1.13%) , Ulnar +median palmar type in 5 hands (2.82%) , Ulnar + median +1<sup>st</sup> dorsal metacarpal artery in 5 hands (2.82%), Ulnar +radial proper 2 hands (1.13%) , Ulnar + 1<sup>st</sup> dorsal metacarpal artery in one hand (0.56%) , Ulnar + 1<sup>st</sup> palmar metacarpal artery in 8 hands (4.52%).

**Conclusion:** We found different patterns of SPA and the prevalence of these different types and subtypes of SPA was quite variable when compared with previous studies. This emphasizes need of wide spread study of SPA in all geographical areas to find out types and subtypes of SPA. The knowledge of such anatomical variations is very important for the surgeons and equally important for the anatomists, to help in enhancing the knowledge of the medical students, so that they can deal with such type of cases in their clinical practice.

**Key words:** SPA, Arch type, Non-arch type, Ulnar dominant, Co-dominant, Ulnar pattern.


## \*Correspondence to:

Rakhee Y Dhongade, Tutor, Department of Anatomy, PIMS' Rural Medical College, Loni, Ahmednagar, MH, India.  
Email: rakheedhongade2013@gmail.com

## Article History:

Received: 23-03-2016, Revised: 05-04-2016, Accepted: 28-04-2016

## Access this article online

Website: www.ijmrp.com	Quick Response code 
DOI: 10.21276/ijmrp.2016.2.3.010	

## INTRODUCTION

The general pattern of arterial supply of the hand consists of two systems of arteries for the volar aspect and single system of artery for the dorsal aspect. The volar supply is contributed by superficial and deep palmar arches.

The superficial palmar arch is an arterial arcade and dominant vascular structure of the palm. It is localized just deep to palmar apponeurosis and is superficial to the digital branches of the median nerve, long flexor tendons of the fore arm and lumbricals of the palm. The arch is formed by superficial terminal branch of the ulnar artery and can be completed to lateral side by superficial palmar branch of radial artery or arteria princeps pollicis or arteria radialis indicis or median artery which accompanies the median nerve. Conventionally, the superficial

palmar branch of the ulnar artery (SPUA), the superficial palmar branch of the radial artery (SPRA) and arteria radialis indices are described as contributing vessels in the formation of superficial palmar arch (SPA) with the ulnar artery as the main feeding vessel<sup>1</sup>.

Variations are more commonly encountered with SPA as reported in previous studies<sup>2-4</sup>. The most of the variations being present on the radial side, with arch completed by variable way i.e. by the radial artery of the index finger, the main artery of the thumb or the median artery<sup>5</sup>. According to Adachi *in Keen*, there are 3 types of superficial palmar arch. One type "ulnar", which has a minimum or absent contribution of the radial artery; the second type is the "radio-ulnar" and the third is the "median-ulnar", in which the

median artery is strong enough to irrigate the palm of the hand and to be part of the arch<sup>6</sup>.

In recent years the use of radial arteries as an arterial bypass graft is becoming popular among various medical centres. A physiologically complete palmar arch network is necessary for safe harvesting of the RA<sup>7</sup>.

The SPA is the center of attraction for most of the procedures and traumatic events in the hand. The hand surgeon needs to refer to the existence and healthy function of the arch before surgical procedures such as, arterial repairs, vascular graft applications and free and/or pedicled flaps depending on radial or ulnar artery in order to maintain or not to harm the perfusion of the hand and digits.

The SPA is the main vascular structure of the palm, hence the familiarity about the possible variations in its pattern is especially important for the surgeons dealing with reconstructive hand surgeries (congenital malformations, post traumatic deformities or general procedures) and those concerned with restoration of the functional anatomy of the hand.

Keeping the importance of these variations in mind, this study was designed to find out the pattern of palmar arterial arches in the region which may help not only the anatomists but also orthopaedicians and micro vascular surgeons and facilitate better documentation and communication amongst medical professionals in the field.

#### AIMS AND OBJECTIVES

- 1) To observe anatomical patterns of the superficial palmar arch.
- 2) To note different variations in the arch formation.
- 3) To find out the commonest pattern of arch.
- 4) To compare the present study results with previous studies.

#### MATERIALS AND METHODS

During period of three years 177 hands were dissected from embalmed cadavers given to the first year medical students of R.M.C., Loni for routine dissection. The superficial palmar arches were dissected, cleaned and photographed. Palmar aponeurosis was exposed and separated. Variation were compared with normal patterns and were documented and photographed. Specimens showing variations were removed and preserved in 10% formalin for further study.

#### OBSERVATION

Some or other Variations were observed in all 177 specimens dissected. Out of total 177 SPA dissected 99 specimens (55.93%) were having non-arch type SPA and 78 specimens (44.07%) were having arched type of SPA.

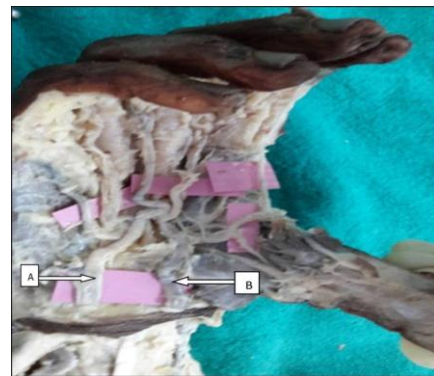**Arch type of superficial palmar arches.** Further classified into 8 subtypes of arches:

1. Ulnar – radiopalmar subtypes: 1. Ulnar-radio pattern in 27 (15.25%) hands (Fig.1)

In this sub type arch is formed by superficial branch of ulnar artery and superficial branch of radial artery. All palmar digital branches are given by arch including thumb.

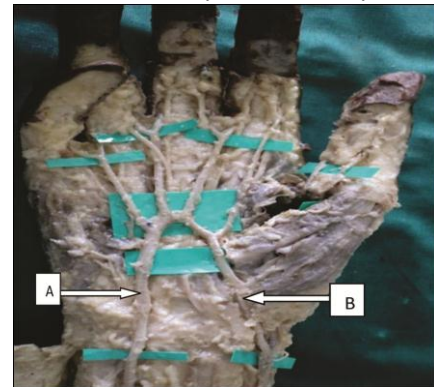
2. Classical pattern in 5 hands [2.82%] (Fig.2)

Arch is formed by superficial branch of ulnar artery and superficial branch of radial artery, all palmar digital branches are given by arch except thumb.



**Fig.1 Ulnar radio pattern arch**

A- Ulnar artery; B- Radial artery

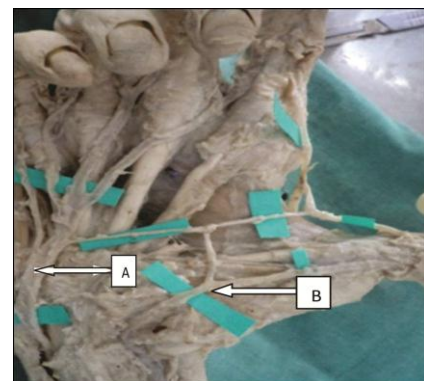


**Fig.2 classical pattern of SPA**

A-Ulnar artery (UA) ; B- Radial artery (RA)

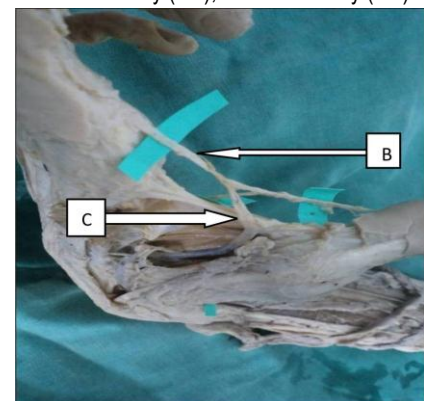
Ulnar +superficial radial +1<sup>st</sup> palmar metacarpal artery; in 6 hands (3.39%) (Fig 3)

Arch is formed by superficial branch of ulnar artery, superficial branch of radial artery and at the 1<sup>st</sup> web space anastomoses with 1<sup>st</sup> palmar metacarpal artery. Dorsal view shown in Fig .4



**Fig 3: SPA formed by ulnar, superficial radial and 1<sup>st</sup> PMA**

A-Ulnar artery (UA);B- Radial artery (RA)

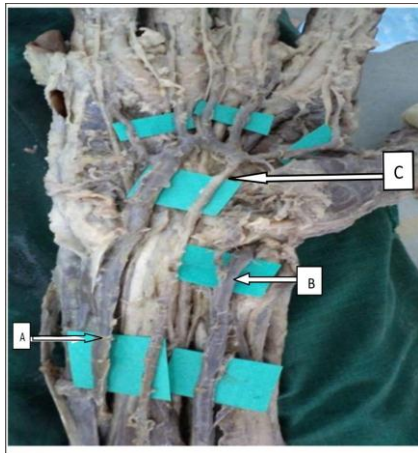


**Fig 4: Dorsal view: 1<sup>st</sup> palmar metacarpal artery**

C - 1<sup>st</sup> palmar metacarpal artery



Ulnar + median palmar type: Formed by anastomosis between the superficial branch of ulnar artery and median artery found in - 8 hands (4.51%) (Fig 5)

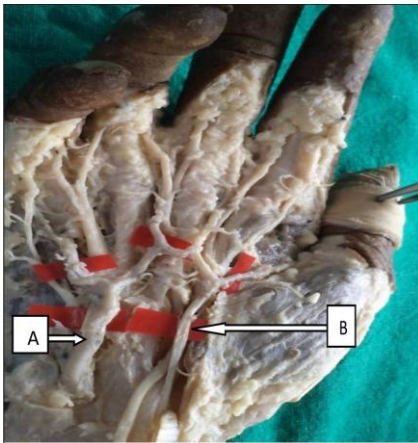


**Fig.5: Ulnar- median palmar type of SPA**

A-Ulnar artery; B – Radial artery; C- Median artery

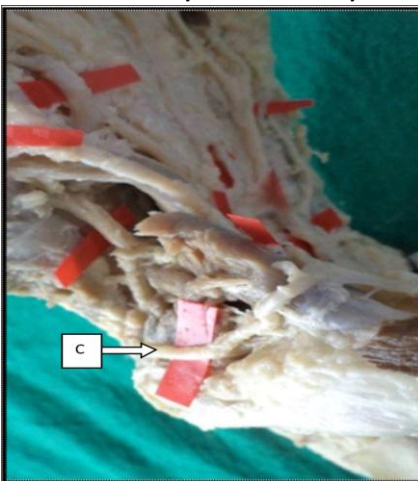Ulnar +median +1<sup>st</sup> dorsal metacarpal artery in 1 hand (0.56%) (Fig 6)

- Arch is formed by superficial branch of ulnar artery and, persistent median artery. At 1<sup>st</sup> web space it anastomoses with 1<sup>st</sup> dorsal metacarpal artery (Fig 7)



**Fig 6: SPA formed by ulnar, Median and 1<sup>st</sup> DMA**

A-Ulnar artery; B- Median artery

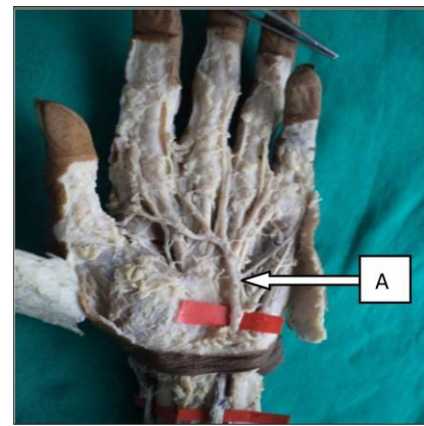


**Fig 7: Dorsal view- 1<sup>st</sup> dorsal metacarpal artery**

c – 1<sup>st</sup> dorsal metacarpal artery

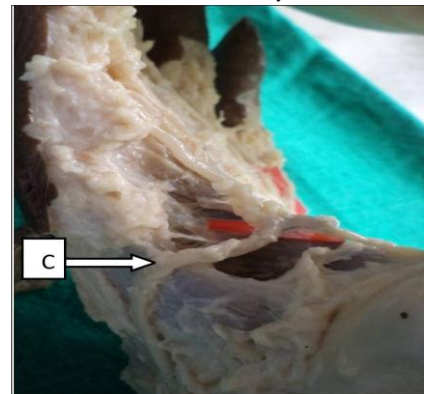
Ulnar + 1<sup>st</sup> dorsal metacarpal artery in 9 hands (5.08%) (Fig 8)

In this subtype, superficial branch of ulnar artery anastomoses with 1<sup>st</sup> dorsal metacarpal artery at 1<sup>st</sup> web space.(dorsal view Fig 9)



**Fig 8: ulnar artery contributing arch formation**

A-Ulnar artery

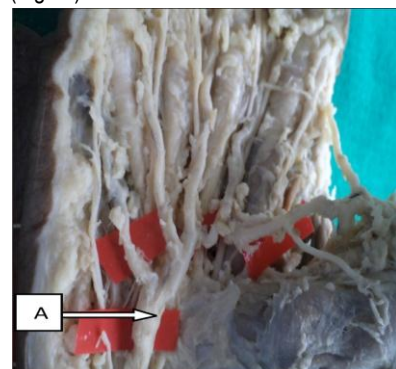


**Fig 9: dorsal view: 1<sup>st</sup> dorsal metacarpal artery**

C- 1<sup>st</sup> dorsal metacarpal artery

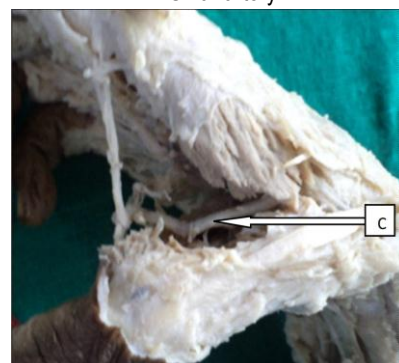
7. Ulnar + 1<sup>st</sup> palmar metacarpal artery in 18 hands (10.16%) (Fig 10)

- In this subtype, superficial branch of ulnar artery anastomoses with 1<sup>st</sup> palmar metacarpal artery at 1<sup>st</sup> web space (Fig 11)



**Fig 10: ulnar artery contributing arch formation**

A- Ulnar artery

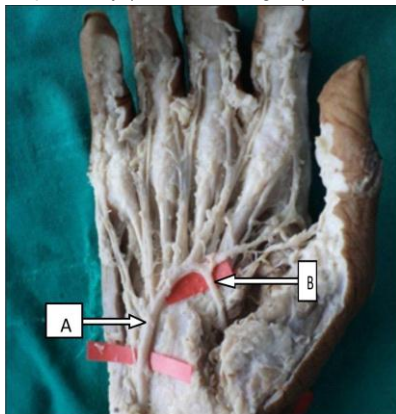


**Fig 11: dorsal view: 1<sup>st</sup> palmar metacarpal artery**

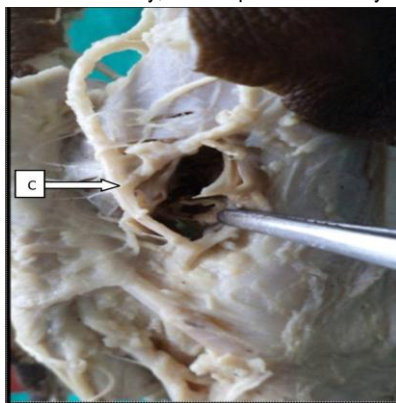
C – 1<sup>st</sup> palmar metacarpal artery

Ulnar + proper radial + 1<sup>st</sup> dorsal metacarpal artery in 4 hands (2.26%) (Fig 12)

Arch is formed by superficial branch of ulnar artery which passes through thenar muscles and anastomoses with deep branch of radial artery and also at 1<sup>st</sup> web space anastomoses with 1<sup>st</sup> dorsal metacarpal artery (dorsal view Fig 13)



**Fig 12: Ulnar artery and proper radial artery contributing arch formation**  
A- Ulnar artery; B – Proper radial artery

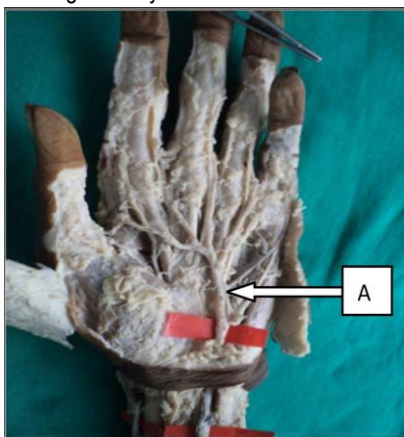


**Fig 13: dorsal view: 1<sup>st</sup> dorsal metacarpal artery**  
C- 1<sup>st</sup> dorsal metacarpal artery

Non arch type further classified in to following subtypes: dominant ulnar type and co-dominant types

**Dominant Ulnar type:** In 62 hands (35.03%) (Fig 14)

- Arch formed only by superficial branch of ulnar artery without anastomosing with any other vessel.

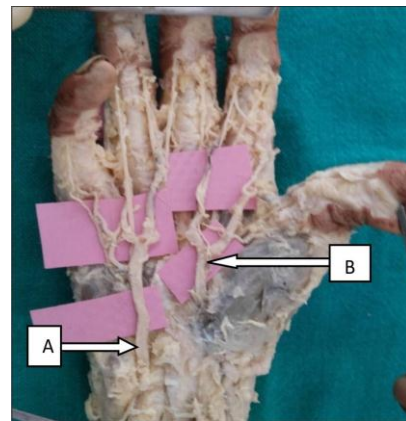


**Fig 14: ulnar artery contributing arch formation**  
A – Ulnar artery

#### Co-dominant types

1. Ulnar + radiopalmar type in 12 hands (7.90%) (Fig 15)

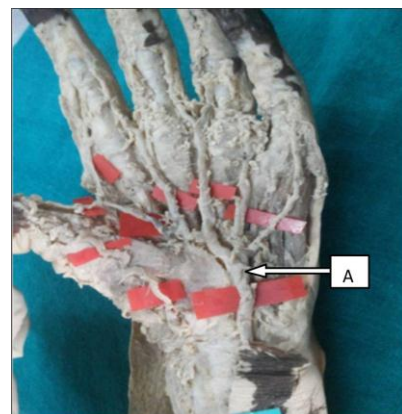
In this sub type, superficial branch of ulnar artery and superficial branch of radial artery enter the palm and supply the hand without anastomosing with each other.



**Fig 15: ulnar-radiopalmar type of SPA**  
A – Ulnar artery; B- Radial artery

2. Ulnar pattern in 2 hands (1.13%) (Fig 16)

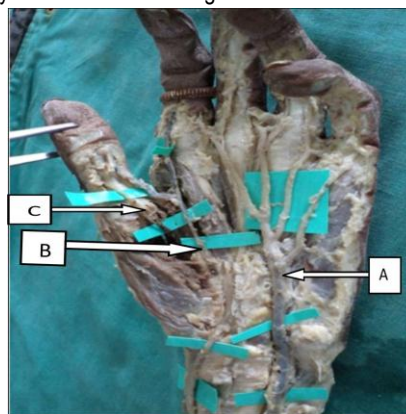
In this subtype superficial branch of ulnar artery and superficial branch of radial artery enter the palm, ulnar artery supplies major portion of hand while radial artery supply radial aspect of thumb only.



**Fig 16: Arch formed by ulnar artery only**  
A- Ulnar artery

3. Ulnar + superficial radial + 1<sup>st</sup> palmar metacarpal artery in 2 hands (1.13%) (Fig 17)

Hand supplied by superficial branch of ulnar artery, superficial branch of radial artery and 1<sup>st</sup> palmar metacarpal artery individually without anastomosing with each other.

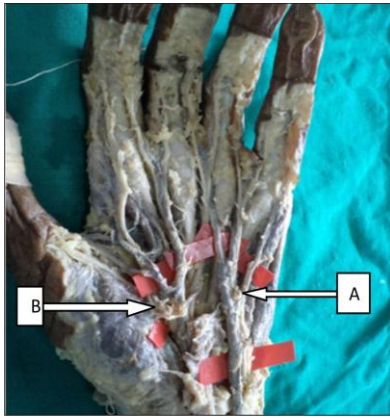


**Fig 17: Arch formed by ulnar, superficial radial and 1<sup>st</sup> metacarpal artery**  
A-Ulnar artery; B- superficial radial artery; C- 1<sup>st</sup> palmar metacarpal artery

4. Ulnar +median palmar type in 5 hands (2.82%) (Fig 18)

Superficial branch of ulnar artery and persistent median artery supply the hand individually without anastomosing with each other.



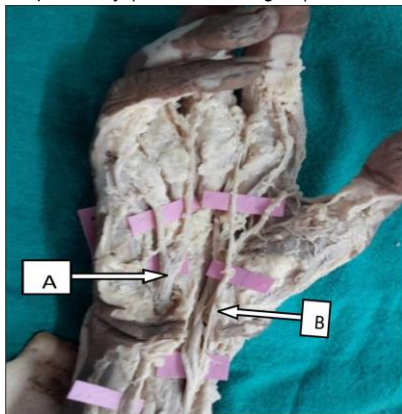


**Fig 18: Arch formed by ulnar and median artery**

A-Ulnar artery; B- median artery

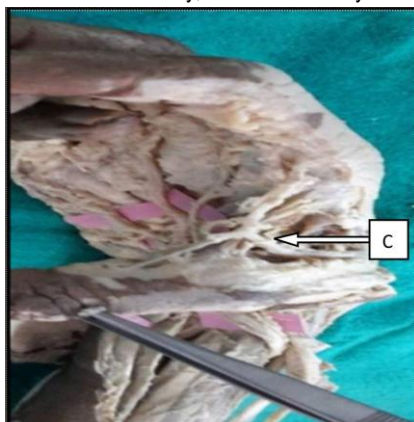
5. Ulnar + median +1<sup>st</sup> dorsal metacarpal artery in 5 hands (2.82%) (Fig 19)

Superficial branch of ulnar artery and persistent median artery enter the hand but do not anastomose with each other but, near to 1<sup>st</sup> web space persistent median artery anastomoses with 1<sup>st</sup> dorsal metacarpal artery (dorsal view Fig 20)



**Fig 19: Arch formed by ulnar, median and 1<sup>st</sup> dorsal metacarpal artery**

A- Ulnar artery; B- Median artery



**Fig 20: dorsal view: 1<sup>st</sup> dorsal metacarpal artery**

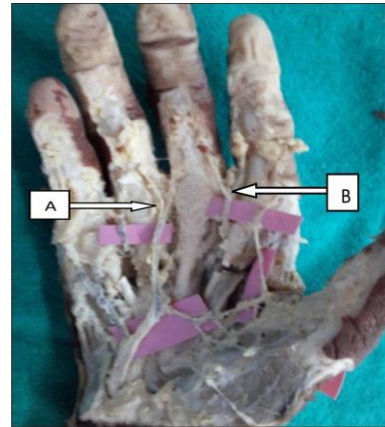
C- 1<sup>st</sup> dorsal metacarpal artery

6. Ulnar +radial proper 2 hands (1.13%) (Fig 21)

In this sub type 1<sup>st</sup> and 3<sup>rd</sup> web space are supplied by superficial palmar arch i.e. by superficial branch of ulnar artery and 2<sup>nd</sup> and 4<sup>th</sup> web by deep arch without anastomosing with each other.

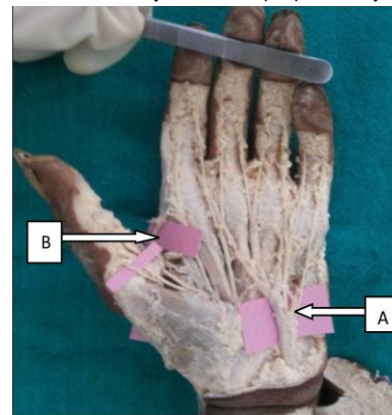
7. Ulnar + 1<sup>st</sup> dorsal metacarpal artery in one hand (0.56%) (Fig 22)

The major portion is supplied by superficial branch of ulnar artery, while both sides of thumb and radial aspect of index finger supplied by 1<sup>st</sup> dorsal metacarpal artery (dorsal view Fig 23)



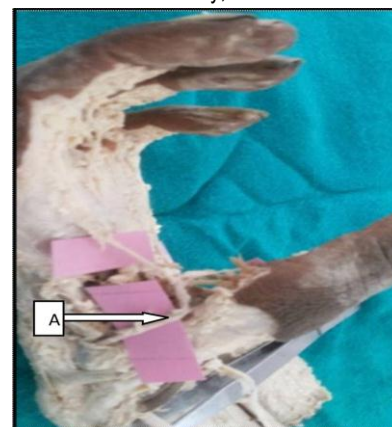**Fig 21: arch formed by ulnar and radial proper artery**

A-Ulnar artery ; B- radial proper artery



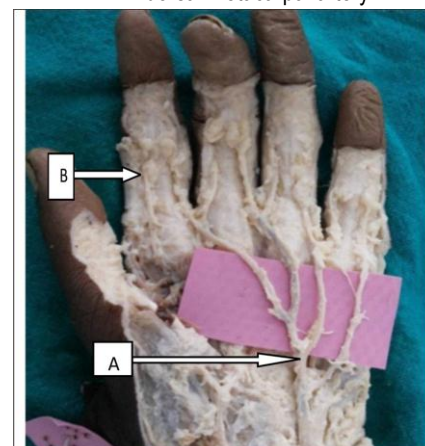
**Fig 22: arch formed by ulnar and 1<sup>st</sup> dorsal metacarpal artery**

A- Ulnar artery; B- 1<sup>st</sup> DMA



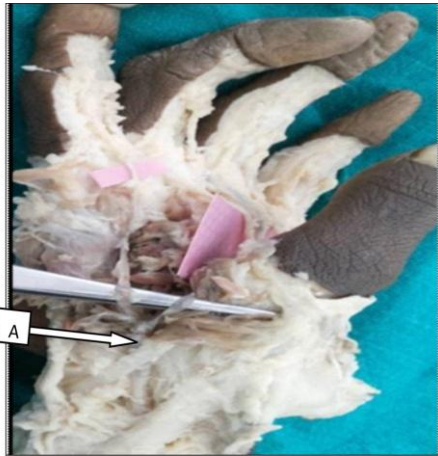**Fig 23: dorsal view: 1<sup>st</sup> dorsal metacarpal artery**

A – 1<sup>st</sup> dorsal metacarpal artery



**Fig 24: arch formed by ulnar and 1<sup>st</sup> palmar metacarpal artery**

A- Ulnar artery; B- 1<sup>st</sup> palmar metacarpal artery



**Fig 25: dorsal view: 1<sup>st</sup> palmar metacarpal artery**

A- 1<sup>st</sup> palmar metacarpal artery

8. Ulnar + 1<sup>st</sup> palmar metacarpal artery in 8 hands (4.52%) (Fig 24)

Major portion of hand supplied by superficial branch of ulnar artery, while both sides of thumb and radial aspect of index finger by 1<sup>st</sup> palmar metacarpal artery (dorsal view Fig 25)

## DISCUSSION AND CONCLUSION

The “traditional classification” consists of linkage between the superficial palmar branches of the radial and ulnar arteries<sup>7</sup>. The “traditional classification” has been reported in as many as 55.9% of specimens in the research of Ikeda et al<sup>8</sup> or as few as in 10% of specimens according to Ruengsakulrach et al<sup>9</sup>.

Olave et al<sup>10</sup> showed in their studies the predominance of the classic palmar arch in 30% and the arch formed by the anastomosis of the ulnar artery and a deep branch of the radial

artery. Ikeda et al. Subdivided SPA into two types i.e. ulnar-dominant (33.2%), radial-dominant (1.4%), and equal types (21.3%). In our study we found only ulnar dominant arch in 62 hands (35.03%) we did not find radial dominance.

Coleman and Anson in their study found incidence of s-I arch [arch type] 34.5% and S-II [Nonarch type] 37%. In our study we found S-I type 44.07% and S-II type 55.93%<sup>11</sup>. Adachi in Keen<sup>6</sup> described the ulnar type as the more popular (59%), followed by the radio-ulnar (32%) and the median-ulnar (9%), this supports our results.

Wide variation was found in various studies with reference to prevalence of complete palmar arch and incomplete palmar arch (Table 1). Developmental anomalies of blood vessels may be due to

- (i) The choice of unusual paths in the primitive vascular plexuses.
- (ii) The persistence of vessels normally obliterated.
- (iii) The disappearance of vessels normally retained.
- (iv) Incomplete development<sup>12</sup>.

The complete arch formed by anastomosis between arteries ensures collateral circulation will be present which may prevent ischemia in case of any injury or blockage of any one of the artery contributing in the formation of arch.

It is obvious that in cases of ulnar dominance the blood supply to hand will not be significantly affected by removal of the radial artery<sup>8</sup>. The persistent median artery contributing to the SPA is reported up to 5%, by others (ulnar-median)<sup>13</sup> while our study shows 4.51%, which is comparable. In a study of cadavers, Gellman et al<sup>14</sup> identified 5 variations. The commonest being the radio-ulnar arch, formed by anastomosis between the UA and the superficial volar branch of the RA. In our study we also found this pattern in 27 (15.25%) cases.

**Table 1: Comparison of prevalence of different arches between different studies**

Type of arch	Present study (%)	Coleman & Anson <sup>(11)</sup>	Karlsson & Niechajev <sup>(15)</sup>	Nicolas ottone et al <sup>(4)</sup>	Bilage et al <sup>(2)</sup>
<b>Arch type</b>	44.07	78.5			86.0
<b>Non- arch type</b>	55.93	21.5			14.0
<b>Arch type</b>					
Ulnar art + SBRA	15.25	34.5	32	20.0	34
Ulnar art + SBRA (classical)	2.82			22.1	
Ulnar art. + sup radial + 1 <sup>st</sup> palmar metacarpal	3.39				
Ulnar art. + 1 <sup>st</sup> DMA	5.08			8.0	28.0
Ulnar art. + 1 <sup>st</sup> palmar metacarpal art.	10.16				
Ulnar art + median art.	4.5	3.8	4		
Ulnar + median art. + 1 <sup>st</sup> metacarpal art.	0.56				
Ulnar + proper radial + 1 <sup>st</sup> DMA	2.26				
<b>Non- arch type</b>					
Dominant ulnar	35.03	13.4	64	23.2	14
Ulnar radio palmar	6.78	32		8.3	8.0
Ulnar pattern	1.13				
Ulnar + sup radial + 1 <sup>st</sup> palmar metacarpal	1.13				
Ulnar + median palmar	2.82	3.8		4.7	4.0
Ulnar + median + 1 <sup>st</sup> DMA	2.82				
Ulnar + 1 <sup>st</sup> DMA	0.56				
Ulnar + 1 <sup>st</sup> palmar metacarpal art.	4.52	13.4			
Ulnar + proper radial	1.13				

The other variation of Gellman et al had an incomplete superficial palmar arch, in which there was absence of a direct communication between UA and contributing vessels<sup>14</sup> and we found similar variation in 2 (8.33%) specimens.

Manners-Smith performed a comparative study of the arteries of the limb in different groups of primates and came to the conclusion that many of the variations in the upper limb arteries that occur in human subjects represent retention or a reappearance of primitive patterns, which are normally found in the gorilla, chimpanzee and other primates<sup>16</sup>.

We found various patterns of SPA, classical pattern of superficial palmar arch [SPA] was found only in 2.82% specimens, the arch lies at the level of distal border of out-stretched thumb. Differences found in occurrences of various types of superficial palmar arch in different studies may be because of Ethnic and geographical differences and sample size used in different studies. The variability in the vasculature of the hand is quite frequent therefore, interpretation of vascular studies must be made with caution.

### LIMITATIONS OF STUDY

The study is done on cadavers in specified area and sample size is not very large so we could not explore the topic in more detail. There is need of further exploratory studies pertaining to the same topic in various geographical areas widespread to establish the uniform classification of superficial palmar arches.

### REFERENCES

1. Standring S. Gray's anatomy. The anatomical basis of clinical practice, 40<sup>th</sup>edn.Elsevier, Churchill Livingstone, Edinburgh, 2005:pp894
2. Bilge.O, Pinar.Y,Ozer .M.A, Govsa.F.A morphometric study on the superficial palmar arch. Surgical Radiological Anatomy. 2006; 28:343-350.
3. Patnik, V.V.G, Kalsey G, Singla R K.Palmar arterial arches-A morphological study. Journal of Anatomical Society India.2001; 51(2):187-193.
4. Ottone N E, Prum N, Dominguez M, Medan C et al.Analysis and clinical importance of superficial arterial palmar irrigation and its variation over 86 cases. International Journal of Morphology. 2010; 28(1):157-164.
5. Moraes SRA, Araújo TN, Silva AR, Paula AR, Salgado JL. Morphologic variations of the superficial palmar arc. Acta Cir Bras [serial online] 2003 May-Jun; 18 (3).183-188 Available from URL: <http://www.scielo.br/acb>.

6. Keen JA. Study of the arterial variations in the limbs, with special reference to simetry of vascular patterns. Am J Anat 1961; 108: 245-61.
7. Marios Loukas,Danny Holdman,Shelly Holdman.Anatomical variations of the superficial and deep palmar arches.Folia Morphol. 2005 vol.64 No.2;78-83
8. Ikeda A, Ugawa A, Kazihara Y, Hamada N . Arterial patterns in the hand based on three-dimensional analysis of 220 cadaver hands. J Hand Surg, 1988; 13A: 501-509.
9. Ruengsakulrach P, Buxton BF, Eizenberg N, Fahrer M. Anatomic assessment of hand circulation in harvesting the radial artery. J Thor Cardio Surg, 2001;122: 178-180.
10. Olave E, Prates JC, Mandiola E, Del Sol Calderón M, Gabrielli C. Formaciones arteriales superficiales de la palma de la mano.Rev Chil Anat 1993; 11 (1): 35-40.
11. Coleman S, Anson B. Arterial patterns in the hand based upon a study of 650 specimens. Surg Gynecol Obst, 1961;113: 409-424.
12. Vidhya Ramakrishnan1, Anil kumar Reddy Y 2, Aruna. S3, Balaji Thotakura4, Suba Ananthi5 A Cadaveric Study On Anatomical Variations Of The Superficial Palmar Arch. Int J Med Res Health Sci. 2014;3(1):144-148
13. Mookambica RV,Velayudham Nair,Rema Nair,Somayaji SN,Narendra Pamidi,Venkata R Vollala. Incomplete superficial palmar arch.Int.J.Of Anatomical variations.2010(3);65-66
14. Gellman H, Botte MJ, Shankwiler J, Gelberman RH. Arterial patterns of the deep and superficial palmar arches. Clin Orthop, 2001;383: 41-46.
15. Karlsson S, Niechajev IA. Arterial anatomy of the upper extremity. Acta Radiol. Diag.1982; 23:115-121.
16. Manners Smith, T.The Limb arteries of the primates. Journal of Anatomy & Physiology.1910; 45: 23-64.

**Source of Support:** Nil.

**Conflict of Interest:** None Declared.

**Copyright:** © the author(s) and publisher. IJMRP is an official publication of Ibn Sina Academy of Medieval Medicine & Sciences, registered in 2001 under Indian Trusts Act, 1882.

This is an open access article distributed under the terms of the Creative Commons Attribution Non-commercial License, which permits unrestricted non-commercial use, distribution, and reproduction in any medium, provided the original work is properly cited.

**Cite this article as:** Rakhee Yashwant Dhongade, M. S. Farooqui, R.N.Wabale. Morphological Study of Superficial Palmar Arches and Their Variations. Int J Med Res Prof. 2016; 2(3): 46-52.