

Natal Teeth: A Case Report

Ahsan Inayat^{1*}, Muhammad Owais², Syed Zahid Hassan³, Ayesha Aziz³, Syeda Sehrish Haider³

¹M.D.S Resident, Division of Prosthodontics, Dow University of Health Sciences, Karachi, Pakistan.

²F.C.P.S Resident, Department of Restorative Dentistry, FJDC and Consultant Dental Surgeon, Life Line Hospital, Karachi, Pakistan.

³Houseofficer at Dow University of Health Sciences, Karachi, Pakistan.

ABSTRACT

Natal teeth are those teeth which are present at time of birth. These teeth that erupt within month after the birth are called as neonatal teeth which are considered rare. Both of the condition, that is neonatal and natal teeth is significantly important to both Pediatricians and Paedodontist. This Case report presents a condition of a two day old infant with natal teeth as seen in images below, which required extraction to avoid the risk of interference with its feeding. Radiographs were not taken so it was not sure that the teeth were a premature deciduous teeth or supernumerary.

Keywords: Natal Teeth, Neonatal Teeth, Paedodontist, Premature, Extraction.

INTRODUCTION

The presence of teeth right after or at birth is a rather rare occurrence.¹ These teeth can create complication to the mother and her child that includes; discomfort and difficulty during feeding, laceration to the breast of its mother and aspiration of teeth.^{2,3} The most common natal and neonatal teeth are the mandibular central incisors.⁴

Natal teeth appears as a normal deciduous tooth but however, yellowish in color, Cone shaped, smaller in size then deciduous tooth. Its enamel and dentin are hypoplastic and there is absence or incomplete formation of root.⁵ If any one of the situations occurs, this can need extraction. How-ever if that tooth doesn't involve any problems with breast feeding and the mother is asymptomatic, then no treatment is required.⁶

Massler and Savara in 1950 introduce the used term called as "Natal teeth" for the tooth that is present at birth and "Neo-natal teeth" for that tooth which erupts with-in the first thirty day after birth.¹ The most common natal and neonatal teeth are the mandibular central incisors.⁴


The incidence of both the Natal and Neo-natal teeth has investigated in multiple studies, some of them are mentioned such as Zhu & King reported the incidence of both natal and neo-natal tooth as ranging from 1:716 to 1:30 000, concluded that there is no such relation b/w wound of mother(s) nipple & the presence

*Correspondence to:

Dr. Ahsan Inayat,
B.D.S, M.D.S (Resident)
Division of Prosthodontics
Dow University of Health Sciences,
Karachi, Pakistan.

Article History:

Received: 27-03-2020, Revised: 06-04-2020, Accepted: 30-04-2020

Access this article online	
Website: www.ijmrp.com	Quick Response code 
DOI: 10.21276/ijmrp.2020.6.3.026	

of natal teeth since the tongue is interposed between these teeth and the nipple during breastfeeding⁴, whereas Chow reported an incidence of 1:2000 to 1:3500.⁵

King and Lee reported that the tooth affected most were lower primary central incisors. According to the study by Bodengoff, 85% of natal teeth are lower incisors, 11% upper incisors, 3% lower canines and only 1% are upper canine or molar and trauma can occur only to the baby's tongue during its presence.⁶

Riga & Fede histological described the lesion, which then started to be called Riga-Fede disease which usually occurs in pair & the eruption of more than two natal teeth is rare.⁷ General Dental Practitioners must work or consult a paedodontist for the treatment of patient with natal and neo-natal tooth. Natal teeth are seen more common as compared than neonatal teeth with a ratio of 3:1 with a greater predilection for women.⁸

CASE PRESENTATION

A Newborn infant Two days old was brought to a private dental clinic with complaint of difficulty in feeding mother milk. On clinical examination and evaluation there were multiple pre-mature deciduous teeth present in both of his arches (maxilla and mandible) as seen in Fig (1).

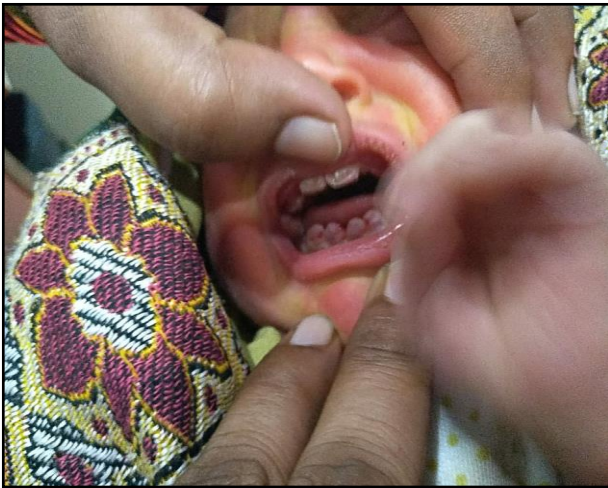

Figure 1: On intraoral examination natal teeth of an infant

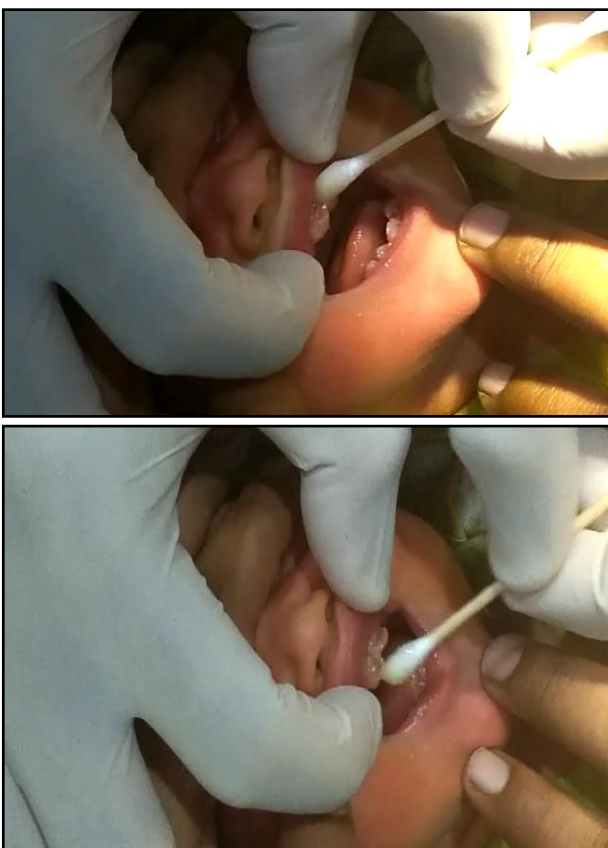

Figure 2: Application of Topical anesthesia to infant for extraction

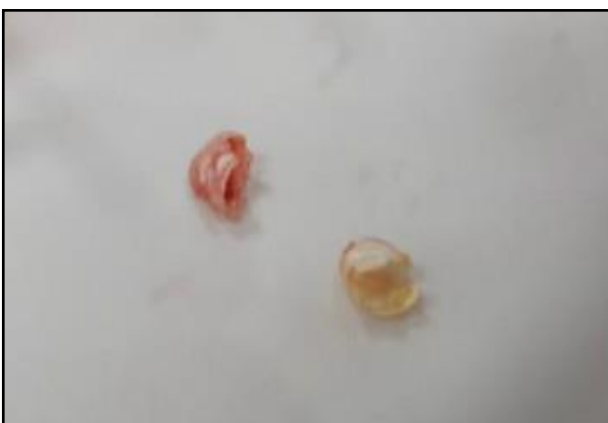

Figure 3: Image showing extracted central incisors.

On taking history from her mother it was showed that the shell-like structure was noted since the time of birth and it interfered her with feeding. The medical and family history was un-remarkable. There was no abnormality detected upon general examination. On examination intraorally, there were yellowish-white shell like with multiple morphological deciduous tooth looking like teeth of approximately 6 mm in width and 5 mm in length were seen on the alveolar ridge of maxilla and the mandible, and were mobile on palpation which attached to the soft tissues. There was no other intra-oral lesions and the tooth. Radiological investigation was not done due to the age. We advised their parent to get them extracted as these teeth because her mother was having difficulty in feeding her child. The teeth were extracted under topical anesthesia as seen in (Fig 2 and 3). Based on its appearance clinically and history it was diagnosed Natal Tooth.

DISCUSSION

Natal teeth are more common than neonatal teeth. The incidence of natal teeth ranges from 1:2,000 to 1:3,000 however the incidence of natal and neonatal teeth varies in different sex, race and population.^{1,6,9} Maintenance of natal teeth in the oral cavity is the first treatment option, unless these teeth would cause any harm to the baby or mother they are required to be addressed through extraction. When these teeth are asymptomatic and are non-mobile, they should be left in the mouth and should only undergo extraction when they produce any inconvenience during breast feeding, or should constitute any risk of aspiration or swallowing.⁵ Natal and neo-natal teeth can be consider as largely as prematurely erupted primary teeth, because in their close resemblance of the primary teeth in site, size, and shape.⁸ By definition, "Natal" teeth are the those teeth which are present at birth and those teeth which erupt during first thirty days of life are called as "Neonatal" teeth, as such its name indicate that these are those tooth that erupt during the 1st month of the baby's life.^{8,10} Existence of natal and neonatal teeth may be able to create a dilemma in the management and treatment planning. Thus, need of intervention is dependent upon the complications and inconveniences that may be produced by its presence in the oral cavity. Therefore, during treatment some of factor should be taken under consideration such as degree of mobility, complication during breast-feeding, traumatic injury to tongue of infant or mother's breast whether the teeth is a normal dentition or a supernumerary tooth.¹¹ The premature eruption causes mobility of the tooth due to incomplete root formation, since the root completion occurs 1½ years after eruption.¹² The supernumerary teeth are mostly conical in shape. Radiographic examination will help to differentiate the supernumerary tooth from a prematurely erupted primary tooth.¹¹ In mandible, they are reported to occur mostly in pairs, while occurrence of single tooth is not uncommon. According to Hebling et al. natal teeth is classified into the following types:-Type-1 that looks like Shell-like appearance of crown with a loose attachment to alveolar mucosa, with no roots, type-2: which is a Solid crown loosely attached to alveolar mucosa, little or no root. In type 3 Incisal edges of crown has just erupted through oral-mucosa and in type 4 mucosal swelling with tooth unerupted but is palpable.⁷ Although etiology is unclear, several factors are considered for the occurrence of natal and neo-natal teeth, which namely includes following, (i) Genetic inheritance (autosomal dominant) (ii) Chemical exposure

(iii) associated syndrome (iv) infection and febrile states (v) malnutrition hypovitaminosis (vi) trauma leading to abnormal location of the developing tooth germ in relation to the alveolar bone.¹³

CONCLUSION

Thus, from previous reported studies it is important to wait until a child gets ten day old before preparing extraction. The importance of waiting time before performing extraction is needed for the microbial flora of intestine which becomes establish as the production to vitamin (K), which is essential for production of prothrombin in liver. If it's not feasible in waiting then it is advisable to evaluate the need of vitamin-K administration by a pediatrician depending upon the condition, if infant isn't medicated by vitamin-K after birth. Vitamin-K (0.5–1.0 mg) is administered I/M to baby to prevent bleeding.

ACKNOWLEDGMENTS

We would like to acknowledge Dr. Muhammad Ziauddin and Dr. Hasan Rizvi, Consultant Dental Surgeon at Life Line Hospital, Karachi, Pakistan to give there valuable time in evaluating the case during the procedure.

PATIENT CONSENT

Consent was taken from infant's parents before starting the procedure and for publishing.

REFERENCES

1. Massler M and Savara B.S, "Natal and neonatal teeth; a review of twenty-four cases reported in the literature," *The Journal of Pediatrics*, vol. 36, no. 3. 349–359, 1950.
2. King NM, Lee AM. Prematurely erupted teeth in newborn infants. *J Pediatr* 1989; 114(5):807–9.
3. Sivapathasundharam B, Logeswari J. Natal Tooth: Case Report. *J Dent Oral Biol*. 2017; 2(17): 1104.
4. Zhu J, King D. Natal and neonatal teeth. *ASDC J Dent Child* 1995;2013:123–8.

5. Chow MH. Natal and neonatal teeth. *J Am Dent Assoc* 1980;2013:215–1614-21.
6. Khandelwal, V., Nayak, U. A., Nayak, P. A., & Bafna, Y. Management of an infant having natal teeth. *BMJ case reports*, 2013, bcr 2013010049
7. J. Hebling, A. Zuanon, and D. Vianna, "Dente Natal—a case of natal teeth," *Odontologia Clinica*, vol. 7, pp. 37–40, 1997
8. Mhaske S, Yuwanati MB, Mhaske A, Ragavendra R, Kamath K, Saawarn S. Natal and neonatal teeth: an overview of the literature. *ISRN Pediatr*. 2013;;95, 62-9.
9. Kumar GS. *Orban's oral histology and embryology*. 13th ed. India: Elsevier Publication; 2014. p. 448
10. Malki GA, Al Badawi EA ,Dahlan MA Natal Teeth: A Case Report and Reappraisal, *Hindawi Case Report in Dentistry*, Vol 2015, Article ID 147580
11. Magitot E. Anomalies in the eruption of the teeth in man. *Br J Dent Sci* 1883;26:640–41.
12. Rao RS, Mathad SV. Natal teeth: Case report and review of literature. *J Oral MaxillofacPathol*. 2009;13:41-6.
13. Sivapathasundharam B. *Shafer's textbook of oral pathology*. 8th ed. India: Elsevier Publication; 2016. pp. 794.

Source of Support: Nil.

Conflict of Interest: None Declared.

Copyright: © the author(s) and publisher. IJMRP is an official publication of Ibn Sina Academy of Medieval Medicine & Sciences, registered in 2001 under Indian Trusts Act, 1882.

This is an open access article distributed under the terms of the Creative Commons Attribution Non-commercial License, which permits unrestricted non-commercial use, distribution, and reproduction in any medium, provided the original work is properly cited.

Cite this article as: Ahsan Inayat, Muhammad Owais, Syed Zahid Hassan, Ayesha Aziz, Syeda Sehrish Haider. Natal Teeth: A Case Report. *Int J Med Res Prof*. 2020 May; 6(3): 130-32. DOI:10.21276/ijmrp.2020.6.3.026