

Tuberculosis of the Common Bile Duct: Rare Cause of Obstructive Jaundice

Mohammad Saief Uddin^{1*}, Zulfiqur R. Khan¹

¹Department of Hepatobiliary and Pancreatic Surgery, Bangabandhu Sheikh Mujib Medical University, Bangladesh.

ABSTRACT

Tuberculosis (TB) is a very rare cause of biliary stricture that is difficult to diagnose and usually requires surgical intervention in order to rule out underlying malignant etiology. A 48-years old man with obstructive jaundice, who was originally thought to have cholangio-carcinoma. He underwent repeated treatments with endoscopic biliary drainage (EBD) and received two schedule of chemotherapy, was finally proved to have tuberculosis of the common bile duct with adjacent tuberculous lymphadenitis. Following exploration of CBD, histopathological report of CBD and lymph node he made a complete recovery.

Keywords: Tuberculosis, Common Bile Duct.

INTRODUCTION

Tuberculosis is a very rare cause of obstructive jaundice. However, with the resurgence of tuberculosis and the emergence of Mycobacterium tuberculosis strains that are resistant to many drugs, biliary tuberculosis may be encountered more frequently in the future. In recent years tuberculosis has been merged as an important disease in developing as well as developed countries, especially with rising incidence of HIV infection.¹⁻³ Abdomen is one of the common sites of extra pulmonary tuberculosis.^{4,5} The main symptoms of TB biliary stricture including jaundice and weight loss are usually indistinguishable from those of other diseases such as cholangiocarcinoma. Histopathologic evidence of caseating granulomatous inflammation with bile cytology revealing M tuberculosis is confirmatory. Polymerase chain reaction is useful to expedite the diagnosis if biliary tuberculosis is being considered. Although the presence of past history or chest X-ray changes of tuberculosis may raise the suspicion of this etiology, most of the reported cases are diagnosed based on surgical pathology. We report here a middle age gentleman who had tuberculous biliary stricture with an excellent outcome after exploration of CBD, t-tube drainage following anti-TB therapy.

CASE PRESENTATION


A previously healthy 48-year-old Bangladeshi male from Satkhira presented with a 4 years history of fatigue, 15 kg weight loss, poor appetite, pruritus, progressive jaundice, dark urine, and pale stool. He had similar history of several occasion and no history alcohol or herbal medicine use. Past history was repeated biliary stenting

*Correspondence to:

Dr. Mohammad Saief Uddin,
Department of Hepatobiliary and Pancreatic Surgery,
BSMMU, Bangladesh.

Article History:

Received: 06-06-2019, Revised: 03-07-2019, Accepted: 18-07-2019

Access this article online	
Website: www.ijmrp.com	Quick Response code 
DOI: 10.21276/ijmrp.2019.5.4.020	

for above complaints. No history of abdominal surgery but history of TB in his family.

Physical examination revealed that he was afebrile and thin with a body mass index of 18 kg/m², muscle wasting, deep yellow sclera, no palpable lymph nodes or stigmata of chronic liver disease. Abdominal examination showed mild hepatomegaly with no remarkable findings in other systems.

Liver enzymes showed a cholestatic pattern with 11.89 mg/dl total bilirubin, 1160 u/L alkaline phosphatase, 360 U/L alanine aminotransferase and 36 g/L albumin. He had normal complete blood count with INR (1.4).

Blood sugar was normal; HBsAg, Anti HCV and Anti HEV were negative. Serum CEA level was 2.6 ng/ml and CA19.9 was <2.50 U/L. Serum creatinine level 1.2 mg/dl.

Chest X-ray showed inflammatory lesion in right cardiophrenic angle. Abdominal ultrasonography (US) showed liver was slightly enlarged with extra- and intra-hepatic biliary dilatation. The diameter of the common bile duct (CBD) was 13 mm. In pancreas a small irregular hypo echoic mass about 23 mm in diameter in the head region.

The patient underwent endoscopic retrograde cholangiopancreatography (ERCP) [Fig 1 and 2] in September, 2004 which revealed lower part of the CBD was normal but mid and part of upper CBD is narrowed and irregular. Rest of the upper part of CBD and intrahepatic biliary tree was dilated. Papillotomy [Fig 1] done and endobiliary prosthesis was implanted. No duodenal or ampullary mass was found.

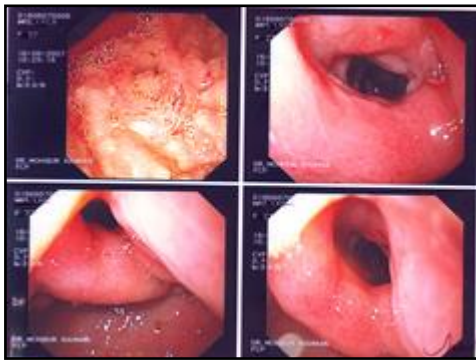


Fig 1: ERCP papillotomy

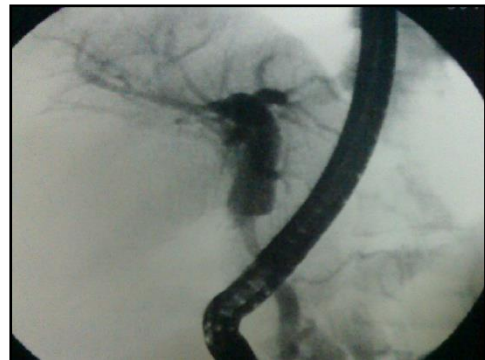

Fig 2: ERCP

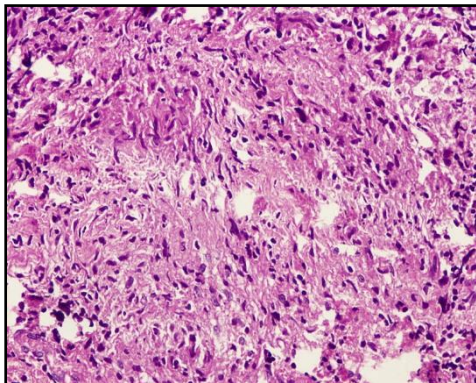


Fig 3: Histopathology shows TB

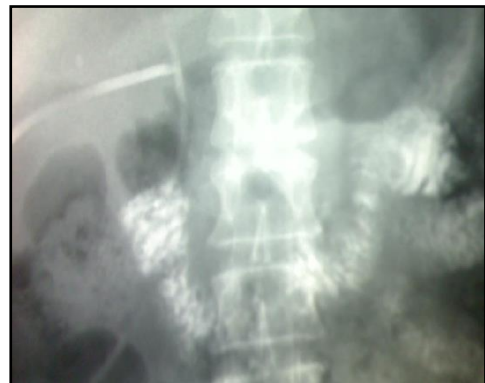

Fig 4: T-tube cholangiogram

On the ground of ultrasound and ERCP finding, cholangiocarcinoma was suspected and patient received 1st schedule of chemotherapy (six cycles). After initial ERCP and stenting patient responded well but previous clinical feature returned in June 2006, so second ERCP was done on 16th June 2006 which showed a 2 cm narrowed segments at the junction of CBD and CHD, Intrahepatic biliary tree was mildly dilated and re-stenting was done due to dislodgement of previous endobiliary stent. Final comments were cholangiocarcinoma with stent dislodgement So the patient has got second schedule of chemotherapy. The patient was well for six months but again developed cholangitis and treated conservatively with antibiotics and upper GI endoscopy was done on August 2007 and the findings were erosive duodenitis, tissue took for biopsy which excluded malignancy.

But features of cholangitis were continued as a recurrent manner. So 3rd ERCP was performed on March 2008. Findings were papillae looks normal, previous stent was seen displaced deep inside the bile duct. Distal CBD looks normal. Filling defect is seen in proximal CBD and distal CHD and intrahepatic intrahepatic biliary channels are dilated. Basket swiping was done. Multiple pigmented stones extracted out. Repeated attempt failed to extract the stent. Re-stenting was done. But still features were not subsided. On May 2008 USG showed SOL in the liver, Gall bladder and pancreas was normal but CBD showed distorted contained echogenic structure suggesting stones. Liver SOL was aspirated and histopathology reported as chronic liver abscess. On this background laparotomy was done on 3rd June 2008. Findings: There was a enlarged lymph node around the cystic duct, the mesenteric lymph nodes were also enlarged. There was a stricture in the supra duodenal portion of CBD.

The CBD was explored it was friable and thick, biopsy was taken from CBD wall and lymph node, finally dilatation was done in the CBD and a t-tube was placed in the CBD. Both of the biopsy reports showed tuberculosis [Fig. 3] and the gall bladder showed chronic cholecystitis.

Anti-TB chemotherapy started on 5th POD. T-tube cholangiogram [Fig. 4] was done on 6th weeks, free flow of bile was seen and t-tube removed after 6 weeks. The patient responded well, felt well and liver function became normal. On the day of writing the report the patient was well.

DISCUSSION

Biliary tuberculosis presents as a triad of fever, jaundice (due to extra or intrahepatic strictures, or hepatolithiasis) and hepatic calcifications.⁶

Based on the location (intra / extra hepatic or both), and nature of obstruction (intramural, extrinsic, or combined), we have classified tubercular biliary strictures in to Type I or extra hepatic [I (i): Intrinsic; I (e): extrinsic]; Type II or Intrahepatic [II (i): Intrinsic; II (e): Extrinsic] and Type III or Both extra and intra hepatic [III (i): Intrinsic; III (e): Combined]. [Sriram et al] The diagnosis can be confirmed by endoscopic biliary brush cytology / biopsy or guided cytology from the enlarged lymph nodes. While presence of acid-fast bacilli (AFB) in the smear is pathognomonic, prior treatment with antibiotics like fluoroquinolones, often makes it impossible to demonstrate AFB. Polymerase chain reaction (PCR) on the endoscopic specimens to demonstrate mycobacterial DNA may be extremely helpful to establish the diagnosis.⁷ 4-drug antitubercular regime is the main stay of treatment, coupled with endoscopic sphincterotomy and stenting in presence of biliary obstruction.⁷

Tuberculous biliary stricture as a cause of obstructive jaundice is extremely uncommon. It involves all parts of the biliary tree, namely the intrahepatic biliary radicles, right and left hepatic ducts, common hepatic duct, cystic duct and CBD.⁸⁻¹⁹

Obstructive jaundice due to biliary TB is most often attributed to mechanical obstruction of the biliary tract by tuberculous lymph nodes or mass lesions. Our patient had tuberculous lymph nodes or mass lesions, but the stricture was due to a secondary endo luminal inflammatory process.

The clinical and cholangiographic features of tuberculous biliary stricture are usually not helpful in differentiating tuberculosis from other common causes of endo-luminal biliary stricture such as primary sclerosing cholangitis or cholangiocarcinoma. Alvarez and Sollano¹⁹ have proposed the characteristic cholangiographic patterns of hepatobiliary tuberculosis, including a tight hilar stricture with dilated intrahepatic ducts, a long smooth stricture involving the mid bile duct, pruning of the distal intrahepatic ducts, and sclerosing cholangitis-like changes. However, the cholangiographic findings in our patient could not be differentiated from those caused by other factors.

Most of the reported cases of tuberculous biliary stricture are diagnosed until laparotomy is performed. In our patient diagnosis was made after surgery and histopathologic findings. The histopathologic findings of tuberculosis include caseating granulomatous inflammation and Langhans giant cells.^{10,16} However, in some cases the diagnosis is achieved by detection of acid fast bacilli (AFB) after staining or culture in the biliary fluid aspirate during ERCP⁹, but the yield of these tests is low. PCR technique for Mycobacterium tuberculosis from biliary fluid may be helpful.^{15,18} Prasad and Pandey¹⁷ reported that AFB of the aspirated bile can diagnose tuberculous biliary stricture.

In our patient, both diagnosis and management were challenging. The diagnosis was difficult because patient receiving chemotherapy as assumed cholangiocarcinoma in ERCP findings but without histologically proved.

The challenge in the management is the high risk of anti-TB hepatotoxicity, especially in the setting of liver cirrhosis. In most of the reported cases, the biliary stricture does not resolve with medical therapy alone and requires surgical intervention and biliary metallic stent placement.^{9,15} However, to our knowledge, biliary stricture is completely resolved only in one case after medical therapy without surgery or permanent biliary drainage procedure.¹⁸ In our patient, the biliary stricture was developed features of obstructive and the reason for this is likely due to permanent fibrotic changes. The jaundice completely resolved after surgery and anti-TB.

In conclusion, biliary tuberculosis causing obstructive jaundice can be completely resolved after surgery along with anti-TB chemotherapy, a high index of suspicion must be kept in mind especially in areas where TB is relatively common.

REFERENCES

1. Barnes PF, Bloch AB, Davidson PT, Snider DE. Tuberculosis in patients with human immunodeficiency virus infection. *N Engl J Med* 1991; 324: 1646-50.
2. Snider DE Jr, Roper WL. The new tuberculosis. *N Engl J Med* 1992; 326: 703-5.

3. Rathi PM, Amarapurkar DN, Parish SS, Joshi J, Koppikar GV, Amarapurkar AD, Kalro RH. Impact of human immunodeficiency virus infection on abdominal tuberculosis in western India. *J Clin Gastroenterol* 1997; 241 (1): 43-8.
4. Marshall JB. Tuberculosis of gastrointestinal tract and peritoneum. *Am J Gastroenterol* 1993; 88: 989-99.
5. Kapoor VK. Abdominal tuberculosis. The Indian contribution. *Indian J Gastroenterol* 1998; 17: 141-47
6. Anand BS, Schneider FE, Zaatari FA, Shawar RM, Clarridge JE, Graham DY. Diagnosis of intestinal tuberculosis by polymerase chain reaction on endoscopic biopsy specimens. *Am J Gastroenterol* 1994; 89: 2248-9.
7. Yeh TS, Chen NH, Jan YY, Hwang TL, Jeng LB, Chen MF. Obstructive jaundice caused by biliary tuberculosis: spectrum of the diagnosis and management. *Gastrointest Endosc* 1999; 50: 105-8.
8. Ratanarapee S, Pausawadi A. Tuberculosis of the common bile duct. *HPB Surg* 1991; 3: 205-8.
9. Bearer EA, Savides TJ, McCutchan JA. Endoscopic diagnosis and management of hepatobiliary tuberculosis. *Am J Gastroenterol* 1996; 91: 2602-4.
10. Behera A, Kochhar R, Dhavan S, Aggarwal S, Singh K. Isolated common bile duct tuberculosis mimicking malignant obstruction. *Am J Gastroenterol* 1997; 92: 2122-3.
11. Valeja R, Pal S, Mann MS, Hadke NS, Bhardwaj M. Isolated common bile duct tuberculosis. *Indian J Gastroenterol* 1999; 18: 125-6.
12. Hickey N, McNulty JG, Osborne H, Finucane J. Acute hepatobiliary tuberculosis: a report of two cases and a review of the literature. *Eur Radiol* 1999; 9: 886-9.
13. Kok KY, Yapp SK. Tuberculosis of the bile duct: a rare cause of obstructive jaundice. *J Clin Gastroenterol* 1999; 29: 161-4.
14. Abascal J, Martin F, Abreu L, Pereira F, Herrera J, Ratia T, Menendez J. Atypical hepatic tuberculosis presenting as obstructive jaundice. *Am J Gastroenterol* 1988; 83: 1183-6.
15. Inal M, Aksungur E, Akgul E, Demirbas O, Oguz M, Erkokoc E. Biliary tuberculosis mimicking cholangiocarcinoma: treatment with metallic biliary endoprosthesis. *Am J Gastroenterol* 2000; 95: 1069-71.
16. Fan ST, Ng IO, Choi TK, Lai EC. Tuberculosis of the bile duct: a rare cause of biliary stricture. *Am J Gastroenterol* 1989; 84: 413-4.
17. Prasad A, Pandey KK. Tuberculous biliary strictures: uncommon cause of obstructive jaundice. *Australas Radiol* 2001; 45: 365-8.
18. Yeh TS, Chen NH, Jan YY, Hwang TL, Jeng LB, Chen MF. Obstructive jaundice caused by biliary tuberculosis: spectrum of the diagnosis and management. *Gastrointest Endosc* 1999; 50: 105-8.
19. Alvarez SZ, JD Jr. ERCP in hepatobiliary tuberculosis. *Gastrointest Endosc* 1998; 47: 100-4.

Source of Support: Nil.

Conflict of Interest: None Declared.

Copyright: © the author(s) and publisher. IJMRP is an official publication of Ibn Sina Academy of Medieval Medicine & Sciences, registered in 2001 under Indian Trusts Act, 1882. This is an open access article distributed under the terms of the Creative Commons Attribution Non-commercial License, which permits unrestricted non-commercial use, distribution, and reproduction in any medium, provided the original work is properly cited.

Cite this article as: Mohammad Saief Uddin, Zulfiqur R. Khan. Tuberculosis of the Common Bile Duct: Rare Cause of Obstructive Jaundice. *Int J Med Res Prof.* 2019 July; 5(4):89-91. DOI:10.21276/ijmrp.2019.5.4.020